

An Evidence-Based Approach to the Conservative Management of Insertional Achilles Tendinopathy

Here's what the latest research says.

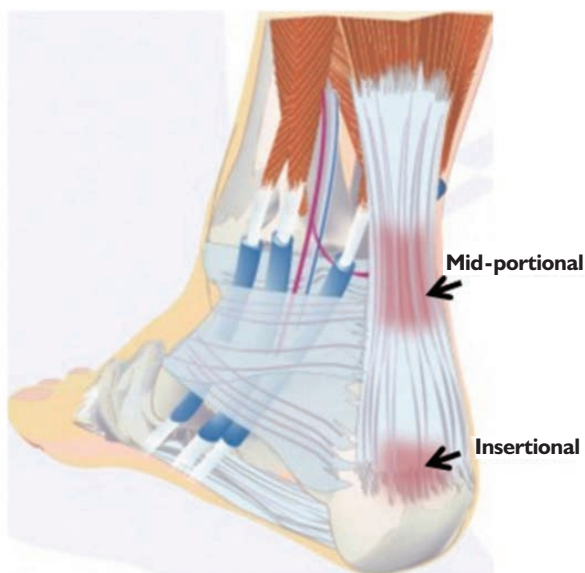BY ROBERT MEIER

Introduction

The Achilles tendon is the strongest and largest tendon in the body, but it is also the most commonly ruptured tendon.¹ The overall incidence of Achilles tendon rupture is on the rise recently because of the aging of the population, growing prevalence of obesity, and increased participation in sports.¹

For all the research that has been done relating to the Achilles and insertional Achilles tendinopathy (IAT), there are still many unanswered questions. Why is the tendon aligned in a spiral or helix? Why are there three insertion points of the Achilles into the calcaneus? Why is the gastroc/soleus complex firing eccentrically at initial contact while the ankle is plantarflexing? We know it's a concentric ankle plantarflexor, but what is the eccentric function of the triceps surae?

Why are outcomes from conservative management so disappointing?² There is a need to drive the development of novel conservative care treatments and to refine existing methods designed to prevent the progression and/or reoccurrence of IAT.^{3,4} The goal of this article is to report



Source: <http://www.foothealth4kids.com.au/conditions/heel-pain-in-kids/insertional-achilles-tendinopathy/>

Figure 1: Anatomy of the Achilles Tendon

data and evidence for developing answers to these questions.

Anatomy

The Achilles tendon (Figure 1) is an incredibly strong structure whose elastic spring-like properties allow it to deliver explosive propulsion during ambulation up to 3500 N before rupture.³ The collagen fibers of the tendon are highly organized structures that demonstrate high


strength in the direction of fiber alignment.³ It originates from the aponeuroses of the gastrocnemius, soleus, and plantaris muscles,⁴ while the soleus inserts medially and the lateral gastrocnemius inserts laterally into the calcaneus.⁵ The inferior facet, or insertion of the superficial component of the Achilles tendon, is composed of the medial gastrocnemius muscle.⁵

The tendon progressively twists as it descends from its origin, causing the gastrocnemius fibers to insert posterolaterally on the calcaneus while the fibers of the soleus insert anteromedially.⁴ The sub-tendons of the Achilles tendon spiral and intertwine as they move laterally and distally towards their insertion sites.^{4,5} Mahan⁵ notes that the twisting allows for greater biomechanical strength. In this literature search, there weren't any other references for any other tendon having a spiral for that purpose.

Risk Factors

There are multiple mechanisms potentially involved as risk factors in

Continued on page 116



Tendinopathy (from page 115)

a person acquiring IAT.⁶ The Achilles has a bimodal age distribution with the first peak in patients between 25 years and 40 years of age and the second peak in those over 60 years.¹ Several authors^{3,5,7,8} note intrinsic factors including anatomic factors, age, sex, metabolic dysfunction, foot cavity, dysmetria, muscle weakness, imbalance, gastrocnemius dysfunction, anatomical variation of the plantaris muscle, tendon vascularization, torsion of the Achilles tendons, slippage of the fascicle, and lateral instability of the ankle. Extrinsic factors noted by the same authors include mechanical overload, constant effort, inadequate equipment, obesity, medications (corticosteroids, anabolic steroids, and fluoroquinolones), improper footwear, insufficient warming or stretching, hard training surfaces, and direct trauma, among others. There is a 3.5 to 1 male to female ratio of IAT.⁸

Multiple authors have reported weakness or dysfunction of the gastrocnemius as a causative factor leading to IAT. The weakness can occur as a result of excessive forces crossing a presumed normal healthy Achilles in the elite athlete population, or normal forces crossing an impaired Achilles in the older diabetic obese population. In either case, the Achilles wasn't strong enough to manage the stress it was being asked to handle. There is only one reference to weak hip abductors being a contributing factor in acquiring IAT.⁹ Research in this area might help explain the spiral configuration of the Achilles.

Incidence

There is general agreement³ that degenerative disorders of the Achilles are common, affecting up to 18% of the adult population with an annual incidence of 6% to 18% in the United States. Achilles tendinopathy is the most prevalent lower extremity tendinopathy, with a 5.9% frequency in sedentary people and around a 50% frequency in elite endurance athletes.¹⁰ In the elite track and field population, middle-distance runners have the highest reported prevalence

of 83%.⁹ Of all the Achilles tendinopathies, IAT comprises 20% to 25% of the injuries.⁹

Mechanism of Injury

There is wide agreement in the literature that IAT is commonly driven by an overuse injury with symptoms that are exacerbated by mechanical loading¹¹ and compounded by chronic failure of the healing response.^{7,12} Kaux postulated that after repetitive mechanical loads and/or when the load exceeds the strength of the tendon, the tendon can become progressively micro- and macroscopically damaged.¹⁰ Put most succinctly, the most common cause of IAT in athletes is excessive loading.⁹ Adding fuel to the fire, the measurement of reduced DF range of motion is not the issue, and that the real issue may rest with (inade-

approximately 50% of these cases.^{2,11} Conservative management is reported to be unsuccessful in 24% to 45.5% of AT patients,⁷ and that surgery is generally recommended after six months of conservative management.⁷ Data from Wirth are a little more optimistic with conservative management providing favorable outcomes for 71% of the cases, with as many as 25% of patients going on to surgery.¹⁵

Conservative Management Protocols

Several authors report that rest and immobilization are used, especially in the acute phase. A number of studies^{1,10,16,17} recommend either a pneumatic walking boot or plastic molded AFO (MAFO) to relieve stress, ensure rest, and prevent excessive ankle dorsiflexion. Park¹

Conservative management has been associated with a higher re-rupture rate compared with operative repair (12.6% vs. 3.5%).

quate) plantarflexor muscle strength (torque/power).¹²

The spiral design of the Achilles plays into the fact that there are three insertion points of the Achilles into the calcaneus. Because of this, different regions of the tendon are subjected to different types of force.^{4,11,13} The superficial side of the tendon is subjected to greater axial tensile strain on both the gastrocnemius and soleus muscles. In contrast, the deep side of the tendon originating from the soleus is subjected to greater transverse compressive strain.¹³

Traditional Conservative Management Success Rates

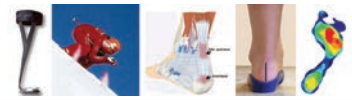
There seems to be universal agreement with Dilger¹⁴ and others that non-operative care is a first line approach for treating IAT, but not everyone is enthusiastic about that approach. Bah⁶ reports that IAT is a painful and debilitating condition that responds poorly to non-surgical interventions. Others report that non-operative treatment will fail in

recommends six to eight weeks of immobilization, but then adds the caveat that prolonged immobilization should be avoided. Other conservative measures mentioned by the same authors include ice, rest, heel lifts, stretching, activity modification, and non-steroidal anti-inflammatory drugs (NSAIDs).

Conservative management has been associated with a higher re-rupture rate compared with operative repair (12.6% vs. 3.5%).¹ After prolonged ankle immobilization in multiple species, structural organization is known to decrease.³ However, recent studies have suggested that the re-rupture rates can be lowered by reducing the period of cast immobilization and using early functional rehabilitation.¹ Functional rehabilitation has proven to be more effective in reducing re-rupture rates than long-term cast immobilization.¹

Recovery from Achilles tendinopathy can take a year or more.⁹ No studies were found specifically com-

Continued on page 117



Tendinopathy (from page 116)

paring recovery times under different conservative management protocols—e.g., with or without immobilization. However, literature does have a lot to say about immobilization.

About Immobilization

In this literature search, the single most common area of agreement among authors is the fact that immobilization leads to disuse atrophy and weakening of the involved structures. The data became obvious in the 1980s when studies showed that loss of motion is designated as a primary cause of chronic pain and re-injury in Achilles management.¹⁹ Later we learned that immobilization results in a smaller quantity of scar tissue that is less able to resist higher loads.²⁰ Reports show that skeletal muscle atrophy attributable to muscular inactivity has significant adverse functional consequences.²¹

Several authors have come to the same conclusion that short-term voluntary immobilization is associated with atrophy and a diminished capacity of the muscle to develop maximal voluntary force.^{22,23,24,25,26} One of the most predictable consequences of cast immobilization is loss of muscle bulk.²³

What's interesting is that the appearance of muscle atrophy masks the actual severity of loss of muscle strength. Chan discovered that with the use of a Molded Ankle-Foot Orthotic (MAFO), the extent of atrophy of the leg muscles on MRI was significantly greater than expected from the clinical examination.²⁷

Very significantly, data show that isometric muscle strength and muscle size declined following immobilization; however, change magnitude was greater for strength than for size.²⁸ And strength loss happens much more quickly than previously thought. The strength of a maximal voluntary contraction is reduced by 24% after two weeks of immobilization.²⁶ To make matters even worse, scarred portions may remain non-recoverably disorganized with associated inferior mechanical properties.³ It's difficult to remember that the primary cause of injury in the first place

was that the structure was too weak to manage the stress it was asked to handle. It's no wonder, then, that evidence-based guidelines on the use of immobilization in the management of common acute soft-tissue injuries do not exist.²⁴

Evolving Conservative Management Protocols

There is a definite trend away from immobilization and towards a more evidence-based approach to managing IAT. Basic science stud-

creased ankle stiffness compared to non-weight-bearing protocols, which could lead to improvements in gait and function.²²

Exercise

Exercise is the primary treatment strategy for all patients with IAT, yet the ideal parameters (type, dose, combination with additional treatments) of exercise are still unknown.¹⁴ Therefore, clinicians often recommend use of a heel lift, particularly during higher level activities.

It's interesting to note that calf/Achilles muscle activation occurs in the frontal (coronal) and not sagittal plane.

ies support the use of non-operative treatment and early active rehabilitation for Achilles tendon ruptures because complete rest and tendon unloading can be detrimental and prolong recovery.⁹ Indeed, previous work has shown that mechanical loading on tendons can induce tendon cell activation, the production of growth factors, tensional homeostasis, remodeling, and nuclear strain transfer.²²

Fatigue testing also supports the concept that early activity leads to better recovery.²² Ultrasound analysis indicated increased matrix alignment (decreased collagen angle deviation) in the more active groups compared to the immobilized group.²² Along with early active rehabilitation, there is some biomechanical evidence to suggest that heel lifts can reduce the amount of tendon elongation (tensile strain) and compression (compressive strain) that occurs at the tendon insertion during daily activities that require ankle dorsiflexion.¹³

Complete rest from all activities during the early phases of treatment may not be necessary.⁹ With a modified eccentric exercise protocol, pain has been shown to decrease from 5.4 at baseline to 3.0 at three months and 1.0 by one year.¹⁴ Early weight-bearing after Achilles injury has also been associated with de-

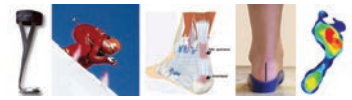
Exercise treatments that require end-range dorsiflexion may aggravate IAT symptoms.¹⁴ These data point to the need for a controlled motion environment to allow mobility and exercise for the foot-ankle complex for strengthening, but within set boundaries to avoid end-range motions for safety.

Importance of Tri-Planar Function

It's interesting to note that calf/Achilles muscle activation occurs in the frontal (coronal) and not sagittal plane. At initial contact (first rocker), the calcaneus is driven from an inverted posture associated with supination during swing to an everted posture associated with pronation during stance. That frontal plane motion triggers a stretch-reflex mechanism to activate calf muscles to eccentrically decelerate the calcaneal eversion moment.²⁹ Therefore, the soleus and the medial gastrocnemius muscles are functional decelerators of calcaneal eversion and subsequent foot pronation due to the bias of their insertion into the medial aspect of the calcaneus.²⁹

The posterior tibialis through its insertion into the plantar anterior medial aspect of the calcaneus also serves to help decelerate calcaneal eversion at initial contact.³⁰ This frontal plane activation of these muscles

Continued on page 118



Tendinopathy (from page 117)

occurs in spite of the fact that gravity and ground reaction forces are driving the ankle into plantarflexion at that time. Decelerating calcaneal eversion also helps decelerate internal or medial rotation of the tibia at initial contact.²⁹ Because it helps decelerate medial tibial rotation, the spiral alignment of the Achilles may have a very functional transverse plane purpose that should be considered when designing a conservative IAT management protocol.

An Evidence-Based Approach to the Conservative Management of IAT

The happy medium between too much stress leading to injury, and not enough stress leading to weak structures getting even weaker, is the concept of controlled stress. Tendon development and healing is a well-orchestrated process requiring highly ordered molecular signaling events influenced by mechanical stimula-



Figure 2: Energy Return AFO

work elsewhere to maintain walking speed.³¹

The newest generation of AFOs are made with carbon composite materials. As opposed to being designed simply to pick up the foot during swing, these carbon composite Energy Return AFOs (ERAFO) (Figure 2) return energy during gait to augment function of the ankle plantarflexor complex.^{32,33,34} This reduces

work elsewhere to maintain walking speed.³¹ The newest generation of AFOs are made with carbon composite materials. As opposed to being designed simply to pick up the foot during swing, these carbon composite Energy Return AFOs (ERAFO) (Figure 2) return energy during gait to augment function of the ankle plantarflexor complex.^{32,33,34} This reduces

within normal ROM limits in the frontal plane. Graded levels of support are available in the prefabricated ERAFOs so the level of support can be matched to the functional needs of the patient. They range from more flexible for the athletic patient population to more supportive for the obese diabetic patients. The design protects against excessive dorsiflexion while facilitating the restoration of near-normal gait parameters.^{33,36}

This could lead to an accelerated return to function while avoiding the effects of disuse atrophy. Simply stated, an injured Achilles tendon will heal faster when subjected to safe dynamic loading.³⁷

Achilles tendon will heal faster when subjected to safe dynamic loading.³⁷

Summary

Medical evidence is clear that IAT is acquired when stress levels crossing the Achilles are beyond its capacity to manage that stress. Evidence is even clearer that immobilization makes weak structures even weaker and impairs and delays healing. The evidence-based environment in which healing can occur involves a foot orthotic/wedge in cases where there is excessive eversion of the calcaneus. Said foot orthotic is placed on the footplate of an ERAFO, and together that combination functions to relieve stress off of and to augment the power of the calf group while limiting disruptive end-range ROM. Early trials have been extremely positive in terms of pain relief, patient satisfaction, and time to return to function. Outcome studies are needed to validate this concept. **PM**

References

- 1 Park SH, Lee HS, Young KW, Seo SG. Treatment of Acute Achilles Tendon Rupture. *Clin Orthop Surg.* 2020;12(1):1-8. doi:10.4055/cios.2020.12.1.1.
- 2 Ricci AG, Stewart M, Thompson D, Watson BC, Ashmyan R. The Central-Splitting Approach for Achilles Insertional Tendinopathy and Haglund Deformity. *JBJS Essent Surg Tech.* 2020;10(1):e0035. Published 2020 Feb 21. doi:10.2106/JBJS.ST.19.00035.

Continued on page 120

Simply stated,

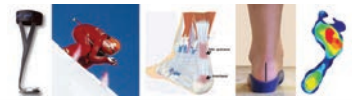
an injured Achilles tendon will heal faster when subjected to safe dynamic loading.

tion.³ A successful non-operative healing strategy may ideally include active recovery and motion, while simultaneously controlling motion to prevent tendon gap formation and subsequent lengthening.²² The challenge is that the essential healing environment needed to restore tendon structure and function has yet to be defined.²²

Traditional MAFOs reduce power crossing the ankle and therefore are not appropriate in the management of IAT. The human ankle produces a large burst of 'push-off' mechanical power late in the stance phase of walking, reduction of which leads to considerably poorer energy economy and the need for more positive

stress across the Achilles, facilitating normal functional ranges of motion while reducing end-range stress. Data show strengthening of the calf group in patients who were switched from a posterior leaf spring MAFO to an ERAFO.³⁵ In addition, the overall satisfaction of users is high, as the appearance is more modern and the function is superior to the existing orthoses.³³

The ERAFO design should include an energy return spring-like footplate linked to an energy return lateral strut leading to a broad pre-tibial shell. The footplate should not immobilize the rearfoot in neutral but accommodate a foot orthotic device/wedge that can help keep the calcaneus functioning



Tendinopathy (from page 118)

³ Freedman BR, Gordon JA, Soslowicz LJ. The Achilles tendon: fundamental properties and mechanisms governing healing. *Muscles Ligaments Tendons J*. 2014;4(2):245-255. Published 2014 Jul 14.

⁴ Chimenti RL, Cychosz CC, Hall MM, Phisitkul P. Current Concepts Review Update: Insertional Achilles Tendinopathy. *Foot Ankle Int*. 2017;38(10):1160-1169. doi:10.1177/1071100717723127.

⁵ Mahan J, Damodar D, Trapania E, et al. Achilles tendon complex: The anatomy of its insertional footprint on the calcaneus and clinical implications. *J Orthop*. 2019;17:221-227. Published 2019 Jun 10. doi:10.1016/j.jor.2019.06.008.

⁶ Bah I, Fernandes NRJ, Chimenti RL, Ketz J, Flemister AS, Buckley MR. Tensile mechanical changes in the Achilles tendon due to Insertional Achilles tendinopathy. *J Mech Behav Biomed Mater*. 2020;112:104031. doi:10.1016/j.jmbbm.2020.104031.

⁷ Aicale R, Oliviero A, Maffulli N. Management of Achilles and patellar tendinopathy: what we know, what we can do. *J Foot Ankle Res*. 2020;13(1):59. Published 2020 Sep 29. doi:10.1186/s13047-020-00418-8.

⁸ Miguel A. Medina Pabón; Usker Naqvi. Achilles Tendonitis. StatPearls Publishing; 2022 Jan.

⁹ Silbernagel KG, Hanlon S, Sprague A. Current Clinical Concepts: Conservative Management of Achilles Tendinopathy. *J Athl Train*. 2020;55(5):438-447. doi:10.4085/1062-6050-356-19.

¹⁰ Kaux JF, Forthomme B, Goff CL, Crielaard JM, Croisier JL. Current opinions on tendinopathy. *J Sports Sci Med*. 2011;10(2):238-253. Published 2011 Jun 1.

¹¹ Chimenti RL, Bucklin M, Kelly M, et al. Insertional achilles tendinopathy associated with altered transverse compressive and axial tensile strain during ankle dorsiflexion. *J Orthop Res*. 2017;35(4):910-915. doi:10.1002/jor.23338.

¹² O'Neill S, Watson PJ, Barry S. WHY ARE ECCENTRIC EXERCISES EFFECTIVE FOR ACHILLES TENDINOPATHY?. *Int J Sports Phys Ther*. 2015;10(4):552-562.

¹³ Chimenti RL, Cychosz CC, Hall MM, Phisitkul P. Current Concepts Review Update: Insertional Achilles Tendinopathy. *Foot Ankle Int*. 2017;38(10):1160-1169. doi:10.1177/1071100717723127.

¹⁴ Dilger CP, Chimenti RL. Nonsurgical Treatment Options for Insertional Achilles Tendinopathy. *Foot Ankle Clin*. 2019;24(3):505-513. doi:10.1016/j.fcl.2019.04.004.

¹⁵ Wirth SH, Andronic O, Aregger F, Jungwirth-Weinberger A, Jentzsch T, Hecker A. Flexor hallucis longus hy-

peretrophy secondary to Achilles tendon tendinopathy: an MRI-based case-control study. *Eur J Orthop Surg Traumatol*. 2021;31(7):1387-1393. doi:10.1007/s00590-021-02891-8.

¹⁶ de Vos RJ, van der Vlist AC, Zwerver J, et al. Dutch multidisciplinary guideline on Achilles tendinopathy. *Br J Sports Med*. 2021;55(20):1125-1134. doi:10.1136/bjsports-2020-103867.

¹⁷ Ferguson A, Christophersen C, Elattar O, Farber DC. Achilles Tendinopathy and Associated Disorders. *Foot Ankle Orthop*. 2019;4(2):2473011419838294. Published 2019 May 10. doi:10.1177/2473011419838294.

¹⁸ Hong-Yun Li and Ying-Hui Hua. Achilles Tendinopathy: Current Concepts about the Basic Science and Clinical Treatments. Hindawi Publishing Corporation, BioMed Research International, Volume 2016, Article ID 6492597, 9 pages, <http://dx.doi.org/10.1155/2016/6492597>.

¹⁹ Balduini FC, Vegso JJ, Torg JS, Torg E. Management and rehabilitation of ligamentous injuries to the ankle. *Sports Med*. 1987 Sep-Oct;4(5):364-80.

²⁰ Bray RC, Rangayyan RM, Frank CB. Normal and healing ligament vascularity: a quantitative histological assessment in the adult rabbit medial collateral ligament. *J Anat*. 1996;188 (Pt 1)(Pt 1):87-95.

²¹ Jackman RW, Kandarian SC. The molecular basis of skeletal muscle atrophy. *Am J Physiol Cell Physiol*. 2004 Oct;287(4):C834-43.

²² Hillin CD, Fryhofer GW, Freedman BR, et al. Effects of immobilization angle on tendon healing after achilles rupture in a rat model. *J Orthop Res*. 2019;37(3):562-573. doi:10.1002/jor.24241

²³ Khalid M, Brannigan A, Burke T. Calf muscle wasting after tibial shaft fracture. *Br J Sports Med*. 2006 June; 40(6): 552-553.

²⁴ Sommerfeldt M, Bouliane M, Otto D, Rowe BH, Beaupre L. The use of early immobilization in the management of acute soft-tissue injuries of the knee: results of a survey of emergency physicians, sports medicine physicians and orthopedic surgeons. *Can J Surg*. 2015;58(1):48-53. doi:10.1503/cjs.004014.

²⁵ Urso ML. Regulation of Muscle Atrophy: Wasting Away from the Outside In: An Introduction. *Med Sci Sports Exerc*. 2009 Sep 2. [Epub ahead of print]

²⁶ White MJ, Davies CT, Brooksby P. The effects of short-term voluntary immobilization on the contractile properties of the human triceps surae. *Q J Exp Physiol*. 1984 Oct;69(4):685-91.

²⁷ Chan KT, Hurlley RA, Dural A, Hayman LA. Improving the Clinical Assessment of Leg Muscle in Adult Clubfoot Using Magnetic Resonance Imaging: A

Case Report. *J Clin Neuromuscul Dis*. 2002 Sep;4(1):23-26.

²⁸ Campbell M, Varley-Campbell J, Fulford J, Taylor B, Mileva KN, Bowtell JL. Effect of Immobilisation on Neuromuscular Function In Vivo in Humans: A Systematic Review [published correction appears in *Sports Med*. 2019 Apr 4;]. *Sports Med*. 2019;49(6):931-950. doi:10.1007/s40279-019-01088-8.

²⁹ Perry J. *Gait Analysis Normal and Pathological Function*. Slack Inc. 1992, 1-55642-192-3.

³⁰ Gray G. *Chain Reaction Seminars*, Wynn Marketing 1993.

³¹ Huang TW, Shorter KA, Adamczyk PG, Kuo AD. Mechanical and energetic consequences of reduced ankle plantar-flexion in human walking. *J Exp Biol*. 2015;218(Pt 22):3541-3550. doi:10.1242/jeb.113910.

³² Bashir AZ, Dinkel DM, Bapat GM, et al. Considerations for Implementation of an Ankle-Foot Orthosis to Improve Mobility in Peripheral Artery Disease. *Arch Rehabil Res Clin Transl*. 2021;3(1):100092. Published 2021 Jan 5. doi:10.1016/j.arrct.2020.100092.

³³ Choo YJ, Chang MC. Commonly Used Types and Recent Development of Ankle-Foot Orthosis: A Narrative Review. *Healthcare (Basel)*. 2021;9(8):1046. Published 2021 Aug 13. doi:10.3390/healthcare9081046.

³⁴ Zou D, He T, Dailey M, et al. Experimental and computational analysis of composite ankle-foot orthosis. *J Rehabil Res Dev*. 2014;51(10):1525-1536. doi:10.1682/JRRD.2014-02-0046.

³⁵ Meier R, Ruthsatz D, Cipriani D. Impact of AFO design on calf circumference. *Lower Extremity Review* 2014;6(10) 1-4.

³⁶ Kearney RS, Lamb SE, Achten J, Parsons NR, Costa ML. In-shoe plantar pressures within ankle-foot orthoses: implications for the management of Achilles tendon ruptures. *Am J Sports Med*. 2011 Dec;39(12):2679-85. Epub 2011 Sep 9.

³⁷ Thevendran G, Sarraf KM, Patel NK, Sadri A, Rosenfeld P. The ruptured Achilles tendon: a current overview from biology of rupture to treatment. *Musculoskeletal Surg*. 2013;97(1):9-20.



Robert Meier is an ABC certified orthotist. He has specialized in closed chain functional biomechanics and gait for most of his 45-year career. He has earned 6 U.S. patents involving applied biomechanics of the spine and lower extremity. Bob currently serves as a consultant to Allard USA.