

# Split and Full-Thickness Skin Grafts for the Treatment of DFUs

These are excellent tools in a surgeon's wound care arsenal.

BY MATTHEW MCCABE MS, DPM, JAMES WHELAN, DPM, AND ROBERT GREENHAGEN, DPM

A DFU can be challenging to treat due to complicating factors including faulty biomechanics, poor glycemic control, peripheral neuropathy, smoking, increased glycosylation of soft tissue, pressure, wound bioburden, peripheral vascular disease and an impaired immune response.<sup>4,7</sup> Foot and leg ulcerations are among the leading causes of hospitalization<sup>2</sup> among diabetic patients. Additionally, one in five infected diabetic ulcers leads to amputation.<sup>8</sup>

Standard wound care regimen involves routine debridement, successful treatment of infection, adequate blood supply, and off-loading. However, despite optimizing these prerequisites for wound healing, at least 30% of the ulcers fail to heal within 20 weeks of treatment.<sup>9</sup> An ulcer that has been present for 4 weeks is at a critical point in the healing process. Sheehan, et al. found that there is a 9% chance of healing an ulcer at 12 weeks when the ulcer has less than 50% area reduction at 4 weeks.<sup>10</sup> The use

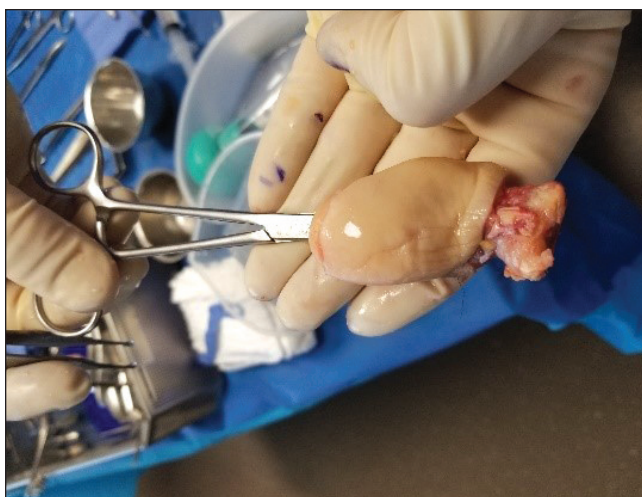


Figure 1a: The hallux was amputated at the metatarsophalangeal joint. Care is taken to not violate the skin that will be used as the full-thickness graft. The outline of the skin graft is incised using a scalpel.

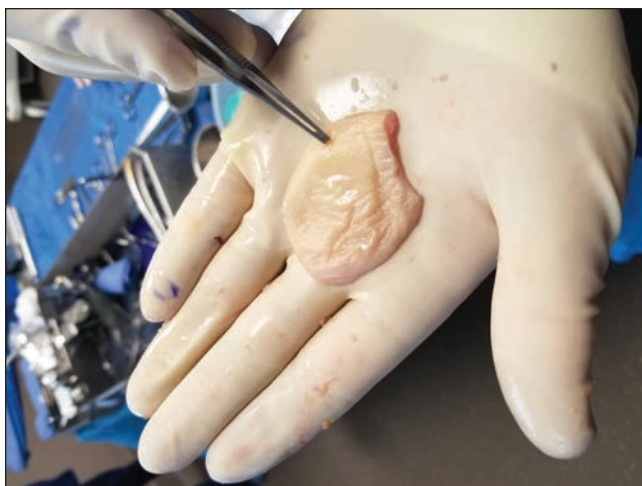

Figure 1b: The graft is harvested using a #10 or #20 scalpel. The same blade is then used to debulk the graft by "scraping off" the subcutaneous tissue.

of advanced products and grafting should be reserved for recalcitrant wounds that have stalled. Today, several options are available, ranging from cryopreserved tissue, live amniotic cells, allografts, xenografts, and autografts. Both full-thickness skin grafts (FTSGs) and split-thickness skin grafts (STSGs) are viable options.

## Evidence-Based Review of Split and Full-Thickness Skin Grafts in Chronic Ulcerations

Split-thickness skin grafts (STSGs) and FTSGs offer a variety of advantages and disadvantages. Grafting options should be carefully considered prior to application. Regarding STSGs, donor site morbidity can be problematic. Inherent morbidities to the STSG donor sites include long periods of healing, pain, scar formation, and undesirable esthetics.<sup>11</sup> An STSG requires more post-operative care in several circumstances.<sup>12</sup> An FTSG may be a better alternative when the goal is to eliminate donor site complications.

Additionally, an FTSG offers improved esthetics,

*Continued on page 120*

# THE DIABETIC FOOT

## Skin Grafts (from page 119)

less shrinkage, reduced post-operative pain, and reduced scar formation.<sup>13-16</sup> Full-thickness skin grafts fre-

had no effect on healing.<sup>2</sup> Another study by Bahita evaluated the success of STSGs on complex wounds with

**Split-thickness skin grafts have been found to be a promising option in the treatment of difficult ulcerations.**

quently include glabrous skin that retains a greater number of epithelial cells and thicker collagen, making it more durable and ideal for plantar DFUs.<sup>17,18</sup>

a subset of the population involving DFUs. Their study reported an average healing rate of 82.4% and a

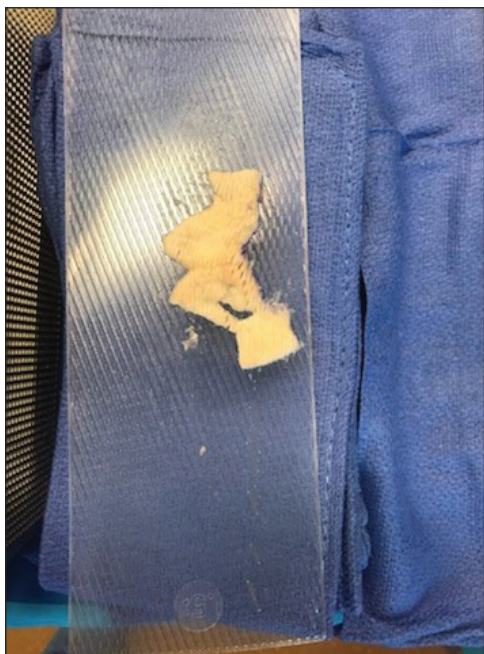

Figure 2: The skin from the amputated toe is placed in a mesher to allow drainage and reduce chances of hematoma or seroma formation.

Split-thickness skin grafts have been found to be a promising option in the treatment of difficult ulcerations. Anderson and colleagues examined the effectiveness of STSGs in the treatment of diabetic foot or leg ulcerations. In their retrospective review, the authors report a healing rate that ranged from 3 to 16 weeks with an average healing time of 5.1 weeks. Ninety percent of the ulcers were healed by 6 weeks. They found that comorbidities including smoking, diabetes and ESRD

mean time to healing of 7 weeks.<sup>19</sup>

There is a paucity of literature that explores the effectiveness of FTSGs in the treatment of chronic foot ulcers; however, the literature that does exist is optimistic. Ramanujam, et al. published a case report involving the use of several full thickness pinch grafts harvested from the plantar forefoot to cover a plantar medial arch DFU. In their study, patients healed at an average of 6.8 weeks.<sup>20</sup>

Lalehparvar and colleagues utilized a pinch graft harvested from the sinus tarsi for coverage of a surgical wound following excision of a cutaneous horn on the plantar foot of a non-diabetic patient. After excision, pathology reports confirmed malignancy. Their technique was successful with no recurrence.<sup>21</sup>

*Continued on page 121*

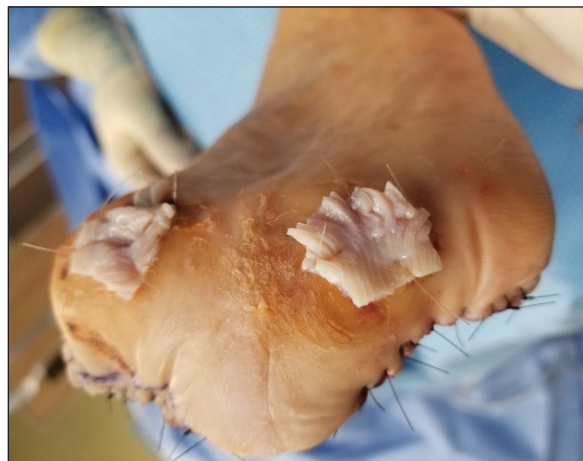

Figure 3: The graft is sutured to the recipient site with 3-0 Monocryl. The surgeon may use a cellular placental graft (Graftix) to improve graft healing and take. The CTP is laid onto the skin graft.

**In their retrospective review, the authors report a healing rate that ranged from 3 to 16 weeks with an average healing time of 5.1 weeks.**

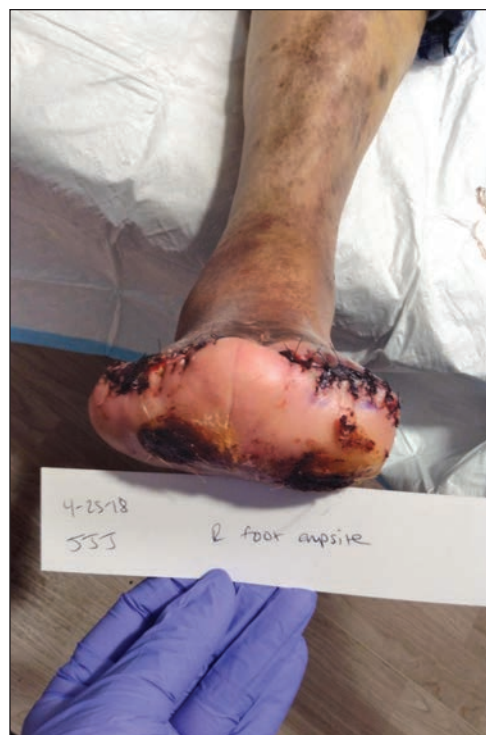

Figure 4: Status-post week 2 with well-healing amputation sites and healed full-thickness skin graft. The use of the graft allowed the patient to undergo a transphalangeal amputation instead of a more proximal procedure such as a transmetatarsal amputation.

*Skin Grafts (from page 120)*

## **Pilot Study**

The authors have completed a pilot study on the use of FSTGs used as treatment for chronic non-healing ulcerations. The FSTGs were harvested as an autograft from an amputated toe at the time of surgery. This technique allows treatment concurrent ulcerations to be addressed without the need for a more proximal amputation such as a ray resection or transmetatarsal amputation. By sparing the length, this improves function and reduces the negative biomechanical effect of the more proximal amputation. In the present pilot study, 82% of patients were reported as healed at an average of 8.4 weeks. This technique also provides the opportunity to harvest plantar skin with no risk of donor site morbidity.

## **Technique and Pearls**

The authors always begin with

the digital amputation (Figure 1a). The amputated toe is kept in warm saline while the graft site is prepared. The full-thickness graft is harvested by using a fresh scalpel. The graft is outlined by cutting the

any fatty or subcutaneous tissue from the graft. The graft is then meshed using a 1:1.5 meshing plate. This allows fenestration of the graft to improve take and reduce risk of hematoma or seroma (Figure 2).

---

**The graft is outlined by cutting the borders of the graft with a scalpel. Ideally, the graft should be taken from the plantar skin if possible.**

---

borders of the graft with a scalpel. Ideally, the graft should be taken from the plantar skin if possible. The graft is then lifted using a forceps and a larger scalpel blade such as #10 or #20. This larger blade reduces the risk of creating a “button-hole” in the graft (Figure 1b).

The maximal amount of skin should be harvested. The same scalpel blade is then used to “scrape”

The graft is then sutured in place using either an absorbable or non-absorbable suture. The authors use a 3-0 Monocryl as the primary suture (Figure 3). The authors prefer to use a cellular amniotic tissue product (Grafix Prime) over the graft to improve graft take. A bolster dressing or negative pressure wound dressing is then placed on the graft. The dress-

*Continued on page 122*

## Skin Grafts (from page 121)

ing is changed 5 to 7 days after the surgical procedure. The site is then hydrated with a hydrogel, and a light dressing is applied daily. Sutures are usually removed after 3 to 4 weeks.

tors in Type 2 Diabetic Patients: A Five-year Observational Study. *Korean Diabetes J* 2009;doi:10.4093/kdj.2009.33.4.315.

<sup>8</sup> Rose JF, Giovinco N, Mills JL, Najafi B, Pappalardo J, Armstrong DG. Split-thickness skin grafting the high-risk diabetic foot. *J Vasc Surg*. 2014 Jun;59(6):1657-63.

<sup>9</sup> Margolis DJ, Allen-Taylor L, Hoffstad

comprehensive histological, histochemical and immunohistochemical analysis. *Histochem Cell Biol*. 2018 Aug 11.

<sup>19</sup> Bhatia A. Epidermal skin grafting in patients with complex wounds: a case series. *J Wound Care*. 2016 Mar;25(3):148, 150-3.

<sup>20</sup> Kim S, Chung SW, Cha IH. Full thickness skin grafts from the groin: donor site morbidity and graft survival rate from 50 cases. *J Korean Assoc Oral Maxillofac Surg*. 2013 Feb;39(1):21-6.

<sup>21</sup> Schwanholt C, Greenhalgh DG, Warden GD. A comparison of full-thickness versus split-thickness autografts for the coverage of deep palm burns in the very young pediatric patient. *J Burn Care Rehabil*. 1993 Jan-Feb;14(1):29-33.

## Autografts have been shown to yield favorable results in the treatment of DFUs.

### Conclusions

DFUs remain a difficult problem for podiatric surgeons. Autografts have been shown to yield favorable results in the treatment of DFUs. Skin grafts are an excellent tool in a surgeon's wound care arsenal. When optimized, a patient can experience healing rates that are similar to rates when biological products are used. **PM**

### References

<sup>1</sup> Bakker, K, Schaper, NC: The development of global consensus guidelines on the management and prevention of the diabetic foot 2011. *Diabetes Metab Res Rev* 2012;doi:10.1002/dmrr.2254.

<sup>2</sup> Anderson, JJ, Wallin, KJ, Spencer, L: Split thickness skin grafts for the treatment of non-healing foot and leg ulcers in patients with diabetes: A retrospective review. *Diabet Foot Ankle* 2012;doi:10.3402/dfa.v3i0.10204.

<sup>3</sup> Ramanujam, CL, Han, D, Fowler, S, Kilpadi, K, Zgonis, T: Impact of Diabetes and Comorbidities on Split-Thickness Skin Grafts for Foot Wounds. *J Am Podiatr Med Assoc* 2013;doi:10.7547/1030223.

<sup>4</sup> Noor, S, Khan, RU, Ahmad, J: Understanding Diabetic Foot Infection and its Management. *Diabetes Metab Syndr Clin Res Rev* 2016;doi:10.1016/j.dsx.2016.06.023.

<sup>5</sup> Brem, H, Sheehan, P, Boulton, AJM: Protocol for treatment of diabetic foot ulcers. *Am J Surg* 2004;doi:10.1016/S0002-9610(03)00299-X.

<sup>6</sup> Svensson, H, Apelqvist, J, Larsson, J, Lindholm, E, Eneroth, M: Minor amputation in patients with diabetes mellitus and severe foot ulcers achieves good outcomes. *J Wound Care* 2011;doi:10.12968/jowc.2011.20.6.261.

<sup>7</sup> Park, S-A, Ko, S-H, Lee, S-H, Cho, J-H, Moon, S-D, Jang, S-A, Son, H-S, Song, K-H, Cha, B-Y, Son, H-Y, et al.: Incidence of Diabetic Foot and Associated Risk Fac-

O, Berlin JA. Healing diabetic neuropathic foot ulcers: are we getting better? *Diabetic Med* 2005; 22 (2): 172-6.

<sup>10</sup> Sheehan P, Jones P, Caselli A, Giurini JM, Veves A. Percent change in wound area of diabetic foot ulcers over a 4-week period is a robust predictor of complete healing in a 12-week prospective trial. *Diabetes Care*. 2003 Jun;26(6):1879-82.

<sup>11</sup> Avery CM. Review of the radial free flap: is it still evolving, or is it facing extinction? Part one: soft-tissue radial flap. *Br J Oral Maxillofac Surg*. 2010;48:245-252.

<sup>12</sup> Sidebottom AJ, Stevens L, Moore M, Magennis P, Devine JC, Brown JS, et al. Repair of the radial free flap donor site with full or partial thickness skin grafts. A prospective randomised controlled trial. *Int J Oral Maxillofac Surg*. 2000;29:194-197.

<sup>13</sup> Lutz BS, Wei FC, Chang SC, Yang KH, Chen IH. Donor site morbidity after supra-fascial elevation of the radial forearm flap: a prospective study in 95 consecutive cases. *Plast Reconstr Surg*. 1999;103:132-137.

<sup>14</sup> Avery CM, Iqbal M, Orr R, Hayter JP. Repair of radial free flap donor site by full-thickness skin graft from inner arm. *Br J Oral Maxillofac Surg*. 2005;43:161-165.

<sup>15</sup> Kim TB, Moe KS, Eisele DW, Orloff LA, Wang SJ. Full-thickness skin graft from the groin for coverage of the radial forearm free flap donor site. *Am J Otolaryngol*. 2007;28:325-329.

<sup>16</sup> Ramanujam, CL, Zgonis, T: Pinch Graft Harvesting Technique for Surgical Closure of the Diabetic Foot. *Clin Podiatr Med Surg* 2012;29:585-588.

<sup>17</sup> Lalehparvar S, Mohiuddin A, Labib I. Successful Excision of Cutaneous Horns in the Foot and Application of a Full-Thickness Pinch Skin Graft for Primary Closure. *J Am Podiatr Med Assoc*. 2017 Mar;107(2):158-161.

<sup>18</sup> Vela-Romera A, Carriel V, Martín-Piedra MA, Aneiros-Fernández J, Campos F, Chato-Astrain J, Prados-Olleta N, Campos A, Alaminos M, Garzón I.Characterization of the human ridged and non-ridged skin: a



**Dr. McCabe** is the current Fellow at the Midwest Foot and Ankle Fellowship in Omaha, Nebraska, which focuses on lower extremity reconstruction and amputation prevention. He graduated from Rosalind Franklin University in North Chicago, Illinois with a DPM and MS in Healthcare Administration. Dr McCabe was the first resident at Christus St Patrick hospital in Lake Charles, Louisiana and completed this residency in 2018.



**Dr. Whelan** is a board qualified podiatric surgeon and a current Associate at the Foot and Ankle Center of Nebraska and Iowa in Omaha, Nebraska and Council Bluffs, IA. He graduated from the College of Podiatric Medicine and Surgery at Des Moines University. Dr. Whelan completed his residency training at Wheaton-Franciscan in Milwaukee, Wisconsin and his fellowship training focused on advanced foot and ankle reconstruction and amputation prevention at the Midwest Foot and Ankle Fellowship in Omaha, NE. He serves as an adjunct professor and clinical adjunct instructor for Des Moines University.



**Dr. Greenhagen** is an associate at the Foot and Ankle Center of Nebraska in Omaha, NE. He is a fellow of the American College of Foot and Ankle Surgeons and board certified in both foot surgery and rearfoot/ankle surgery by the American Board of Foot and Ankle Surgeons.