

Reverse Sural Artery Adipofascial Turndown Flap for Ulcerations with Achilles Exposure

The authors delineate why this is a versatile procedure for limb salvage.

BY DAVID POUGATSCH, DPM AND KAREN SHUM, DPM

Introduction

A major challenge to reconstructive limb salvage is coverage of large soft tissue defects with exposed tendon in the lower extremity. The diabetic ulcer, particularly involving the exposure to the Achilles tendon, remains a challenge for the foot surgeon. When these occur in patients with adequate circulation, the reverse sural artery (RSA) flap can serve as a useful tool for their management.¹⁻⁵

Patients with wounds over an exposed Achilles tendon are often faced with a limb-threatening situation. These ulcerations are notoriously difficult to treat because of their late clinical presentation, often involving large skin and soft tissue defects, extension to the Achilles tendon, and insufficient local tissue for closure. Often local simple treatment options have failed. Often the wounds have not responded to a trial of off-loading or have healed with unstable scars and are now subject to recurrent ulceration. Full-thickness soft tissue defects can lead to exposure of deep structures, including the Achilles tendon or calcaneus. In general, tendons are prone to desiccation and often become necrotic, resulting in increased risk of infection. Wounds over the Achilles tendon are particularly precarious because the Achilles tendon functions as a powerful lever arm for propulsion during ambulation. It is imperative that aggressive debride-

ment is performed, but this often leads to compromise or loss of tendon function. In certain populations, this significantly increases morbidity and mortality of patients. Therefore, it is important to provide for adequate wound coverage over the Achilles tendon in order to preserve function.

Although local flaps, such as the advancement, rotation, and transposition flaps, comprised of skin and subcutaneous tissue, can promote healing

The use of this flap is part of an overall strategy for the management of complex posterior ankle ulcerations which require debridement, eradication of infection, and adequate wound bed preparation. Once the ulceration is sufficiently prepared, the patient is ready for the construction of the RSA flap. However, because of the variability of the flap, a detailed angiogram should be obtained prior to the procedure to confirm adequacy of both the

The reverse sural artery flap is typically performed as a distally based fasciocutaneous flap.

of smaller defects, larger ulcers are better treated with flaps of vascularized tissue. These are comprised of muscle, subcutaneous tissue and skin. These are the pediculated fasciocutaneous, adipofascial, and myocutaneous flaps such as the RSA flap. As opposed to a local flap, RSA flaps have an anatomically recognizable arteriovenous system which permits a greater arc of mobility, longer length-to-width ratio, and an increased flap perfusion. Although there is increased risk to vascularity if the dissection is extensive, there is no need for microvascular anastomosis. When the ulceration is greater than 4cm located at the posterior ankle, an RSA flap can be performed.

dorsal and plantar circulation so that the foot circulation will not be compromised because the RSA has been mobilized. This commonly requires complex angiographic imaging with multiple views of the foot and selective arterial catheterization. Often, it is useful to supplement angiographic imaging with Doppler studies (Figure 1).

The reverse sural artery flap is typically performed as a distally based fasciocutaneous flap. In this case, an adipofascial flap was performed based on the RSA, and then a split thickness skin graft (STSG) was applied. The vascularity of this flap is based on the anastomosis between the peroneal artery and the branches of the sural

Continued on page 130

Achilles Exposure (from page 129)

artery accompanying the sural nerve and the lesser saphenous vein. Ideal situations are those where there is enough collateral circulation of the distal leg but inadequate local tissue for coverage—for instance, ulcers 4-6 cm, post-traumatic or post-infective, that have an exposed Achilles tendon. In such a scenario an STSG or local flap may not be an option. Skin grafts will not become incorporated when a peritenon is lacking over the tendon. Also, often skin grafts over mobile tendons cause adhesion, resulting in decreased tendon excursion or breakdown as late sequelae.

The advantages of the reverse sural artery adipofascial flap include: easy to dissect, not necessary to sacrifice important arterial pedicle, wide rotation arc is possible, and a microvascular anastomosis is not necessary. Disadvantages of the procedure include the sacrifice of the sural nerve and

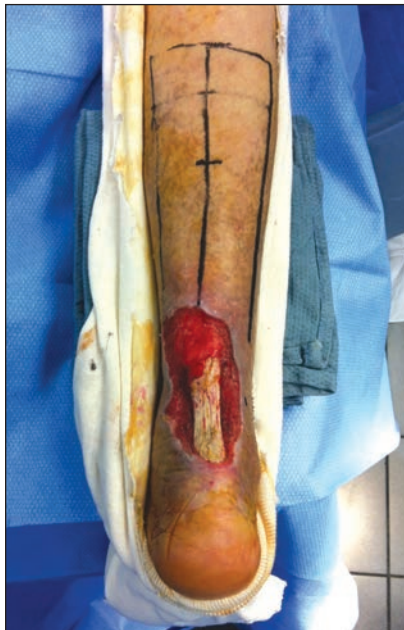

Figure 1: Posterior ankle ulceration with exposed Achilles tendon and large soft tissue defect with proposed incision site marked.

donor site considerations. The donor site requires primary closure or coverage with skin grafts. Contra-indications to performing this procedure include: small ulcerations that can be treated with simpler methods, vascular insufficiency, complicated renal or cardiac issues, non-ambulatory status, severe

infection, unsalvageable foot, and a noncompliant patient.

Intra-operative Pearls

Intra-operative positioning is in the prone position. A tourniquet is recommended to help with visualization. The flap is marked along the axis of the

sural nerve. The defect is measured, and the flap is marked on the posterior or calf area with the maximum length parallel to the sural nerve. Intra-operative Doppler assessment can assist with incision placement. The course of the peroneal artery is marked. The last perforating branch from the peroneal artery is marked 5 centimeter above the lateral malleolus tip. The pedicle length can be evaluated with stretched gauze. The skin incision can be linear, curvilinear, Z shape, or T shape.

The skin is incised and lifted from the underlying tissue. The lateral and medial fascial margins are incised. The lesser saphenous vein, sural nerve, and sural artery are identified and ligated. A portion of the gastrocnemius muscle can be included in the flap. The underlying fascia is elevated from the muscle proximal to distal with a subfascial dissection until reaching the pivot point. The deep fascia is included, taking care to keep the paratenon covering the Achilles tendon. When the base of the flap is wide enough, pedicle visualization is not necessary. The deep fascia can be sutured to the skin to

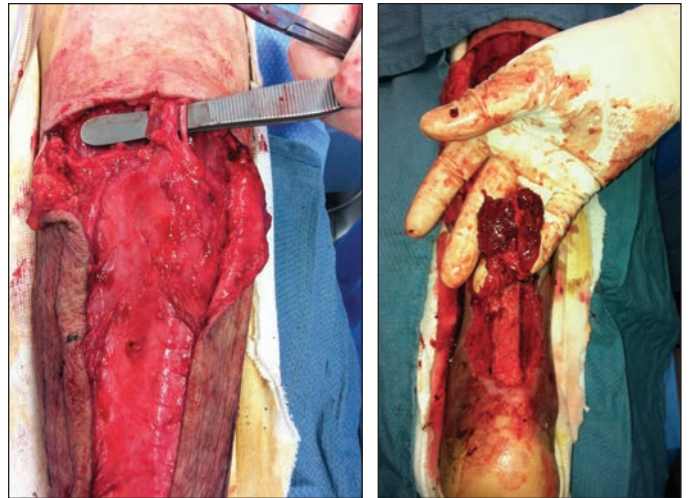


Figure 2: Intraoperative dissection with lesser saphenous vein, sural artery, and sural nerve identified. 2B: Elevated muscle rotated and to be turned down over exposed Achilles tendon.

prevent shearing of the flap. The flap can be mobilized to the defect through a subcutaneous tunnel or not, and covered with STSG to prevent any compression, or it can be left externally and transected four weeks later (Figure 2).

The donor site can be closed primarily if small, or an STSG can be applied. A drain is typically used under the flap.

One-stage vs. Two-stage

Current controversy exists on whether this procedure should be performed as a two-stage or one-stage procedure. In general, a two-stage is recommended if a large pedicle or arc of rotation is planned, and to increase local vascular supply by opening the choke arteries. Supercharging procedures to increase flap vascularity are beyond the scope of this article but can be a consideration intra-operatively. Extrinsic factors such as poor flap design, excessive skin traction, inadequate flap size, twisting or kinking of the flap pedicle, excessive compression, and inappropriate flap design in traumatized or radiated

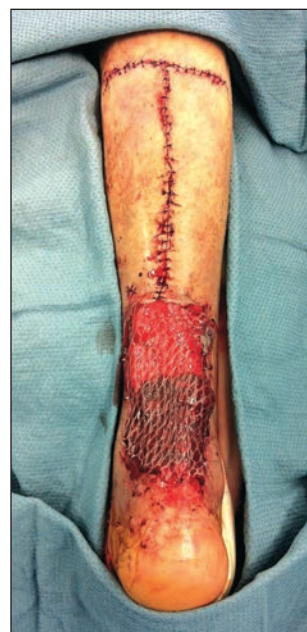

Figure 3: Donor site closed primarily, and recipient site covered with meshed split thickness skin graft obtained from ipsilateral thigh.

Continued on page 131

Achilles Exposure (from page 130)

tissue may lead to flap failure. Other reasons which may lead to flap complications include arteriosclerosis, hypotension, thrombosis, infection, and hematoma (Figure 3).

Conclusion

Coverage of large soft tissue defects with a reverse sural artery flap is a versatile procedure for limb salvage. It is a thin durable flap with good vascularity and relatively few co-morbidities. This is especially beneficial in Achilles tendon wounds where coverage is not always easily attainable. Granulation tissue does not form well over the tendon, and skin grafting is often not suitable over a highly mobile tendinous structure. Additional benefits of a reverse sural artery flap are that it is much quicker and has fewer co-morbidities than free muscles flaps which require long and tedious dissection along with more donor site mor-

bidity. Reverse sural artery flaps can also be used to cover the calcaneus and deep heel wounds. **PM**

References

¹ Tsai J, Liao HT, Wang PF, Chen CT, Lin CH. Increasing the success of reverse sural flap from proximal part of posterior calf for traumatic foot and ankle reconstruction: Patient selection and surgical refinement. *Microsurgery*. May 7 2013.

² Persichetti P, Brunetti B, Aveta A, Segreto F. Reverse-flow medial sural artery perforator flap: pedicle extension for distal lower limb defects. *Ann Plast Surg*. Feb 2013;70(2):246-247.

³ Ignatiadis IA, Tsiampa VA, Galanakis SP, et al. The reverse sural fasciocutaneous flap for the treatment of traumatic, infectious or diabetic foot and ankle wounds: A retrospective review of 16 patients. *Diabet Foot Ankle*. 2011;2.

⁴ Suliman MT. The reverse sural flap: modifications to improve efficacy in foot and ankle reconstruction. *Ann Plast Surg*. Oct 2009;63(4):468.

⁵ Price MF, Capizzi PJ, Watterson PA, Lettieri S. Reverse sural artery flap: ca-

veats for success. *Ann Plast Surg*. May 2002;48(5):496-504.



Dr. Pougatsch is the co-founder and medical director of Wound Institute of America, Inc. He serves as a Clinical Instructor at the College of Podiatric Medicine at Western University of Health Sciences, and is on the teaching staff at Cedars-Sinai Medical Center in Los Angeles. Dr. Pougatsch is board certified by the American Board of Podiatric Medicine with a Certificate of Added Qualification in Amputation Prevention. He can be reached at drp@woundinstitutes.com.



Dr. Shum is the Medical Director of the Amputation Prevention Center at Torrance Memorial Medical Center in Torrance, CA and on the teaching staff at Cedars-Sinai Medical Center in Los Angeles.