

The MIAA Bunion Correction

Here's an MIS approach to the Austin Akin.

BY DON PEACOCK DPM, MS

Introduction

Hallux valgus surgical correction is a common task performed by foot surgeons and is one of the more challenging ones. More than 150 surgical procedures have been developed to correct HAV.¹ In this presentation, the author presents the MIAA technique (Minimally Invasive Austin Akin) which allows for:

- 1) Correction of IM angles up to 17 degrees
- 2) Direct and/or indirect PASA adjustment
- 3) Hallux abductus rectification
- 4) 1st ray length preservation
- 5) Reduction of medial shelf created by the osteotomy
- 6) Removal of the medial bunion prominence
- 7) Fixation options with screws or K-Wire
- 8) An office-based paradigm
- 9) An inexpensive cost-effective process
- 10) Quick surgical times/ 20-25 minutes
- 11) Correction of frontal plane via hallux osteotomy frontal plane rotation.

Historical Perspectives

Percutaneous and minimally invasive foot surgery (MIS) has garnered attention of patients and foot surgeons worldwide. This is especially true in Europe where MIS bunion surgery has undergone several generations of advancement. While these

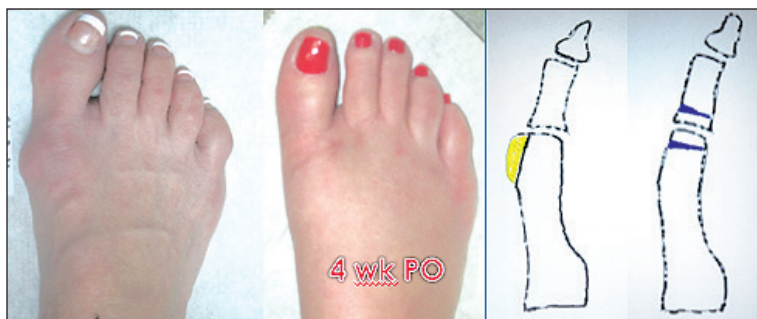

Figure 1: Pre-operative and post-operative views after a Reverdin-Isham bunion correction and a diagram depicting the technique.

procedures have been strengthened in Europe, its foundation took place in the United States. The discipline of MIS foot and ankle surgery was begun by podiatrists in the United States over 50 years ago. These pioneer DPMs gave medicine an in-

dures since the 1970s.

Most forerunner MIS foot surgeons were members of the AAFAS. Dr. Stephen Isham was a podiatrist and Academy member performing MIS foot surgery using techniques he learned from the Academy devel-

through the Academy of Ambulatory Foot and Ankle Surgery (AAFAS). Foot surgeons from both the USA and abroad came to the AAFAS seminars and learned MIS techniques from the pioneers of the discipline. A relatively small band of podiatrists have continued to advance MIS proce-

Percutaneous and minimally invasive foot surgery (MIS) has garnered attention of patients and foot surgeons worldwide.

valuable gift but regrettably, these techniques were rapidly abandoned. The paradigm of omitting MIS procedures was partially due to the lack of theoretical or practical learning opportunities available overseas and the absence of studies of objective outcomes published in the USA. The lack of objective conclusions was the core reason that USA foot surgeons failed to embrace these techniques.

Paradoxically, a USA-based headquarters for learning these procedures became firmly established

operators. He went on to obtain an MD degree and went to Europe to teach these MIS foot surgery techniques to orthopedic surgeons abroad.

The first MIS bunion correction technique to achieve widespread success was the Reverdin-Isham bunion correction.² This first-generation procedure involved a medial wedge osteotomy of the first metatarsal obliquely angled to avoid the sesamoids leaving the lateral cortex intact. It was performed in con-

Continued on page 108

MIAA (from page 107)

junction with a percutaneous Akin procedure also performed with the lateral cortex intact. There was no internal fixation following these osteotomies (Figure 1 and 2).

Second and Third Generation European Techniques

The first-generation MIS bunion correction procedures taught to European orthopedic surgeons went on to gain popularity and were particularly embraced by Spanish orthopedist Dr. Mariano DePrado. Shortly thereafter, second generation techniques were employed by European orthopedic surgeons who utilized a distal transverse osteotomy of the first metatarsal stabilized with an axial wire. These second genera-

tion procedures became known as the Bosch procedure and the SERI procedure (Figure 3).³ Currently, third-generation percutaneous bunion procedures are being performed in Europe. These techniques involve

neous screw fixation allowing for primary bone healing.⁴

Although these third-generation techniques are being touted as new, they were described and applied years ago in the U.S. by Acad-

Currently, third-generation percutaneous bunion procedures are being performed in Europe.

a V-shaped percutaneous osteotomy (Austin/Chevron) combined with a percutaneous Akin osteotomy. These procedures are known as the PECA (percutaneous modified Chevron Akin) or MICA (Minimally Invasive Chevron Akin) and utilize percuta-

emy members. Gorman and Plon described a 60° percutaneous V-shaped osteotomy (Austin) of the first metatarsal for correction of bunion deformity in 1983. This is outlined in their textbook *Minimal Incision Sur-*

Continued on page 109

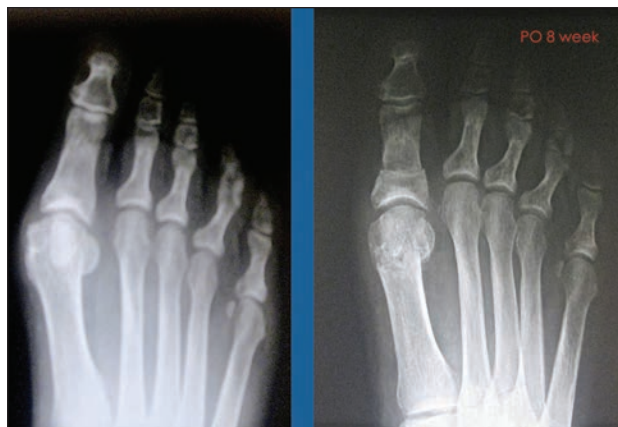


Figure 2: Pre-operative x-rays and post-op eight weeks x-rays following a Reverdin-Isham bunionectomy.

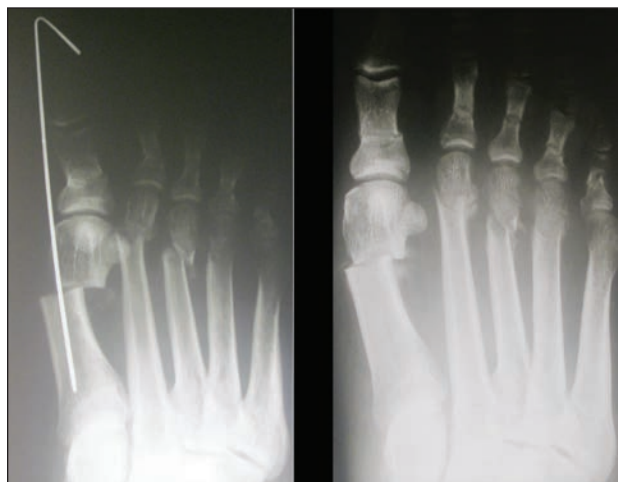

Figure 3: Immediate post-op and eight weeks post-op of a SERI/Bosch MIS bunion correction.

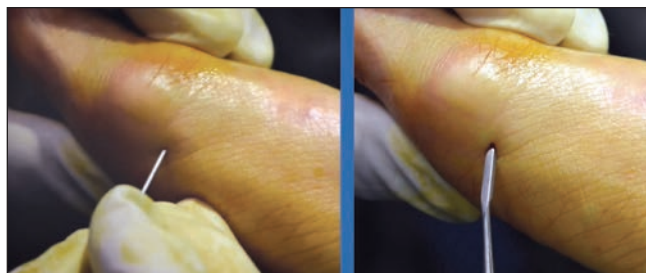

Figure 4: Incision placement for removal of a dorsal medial exostosis.

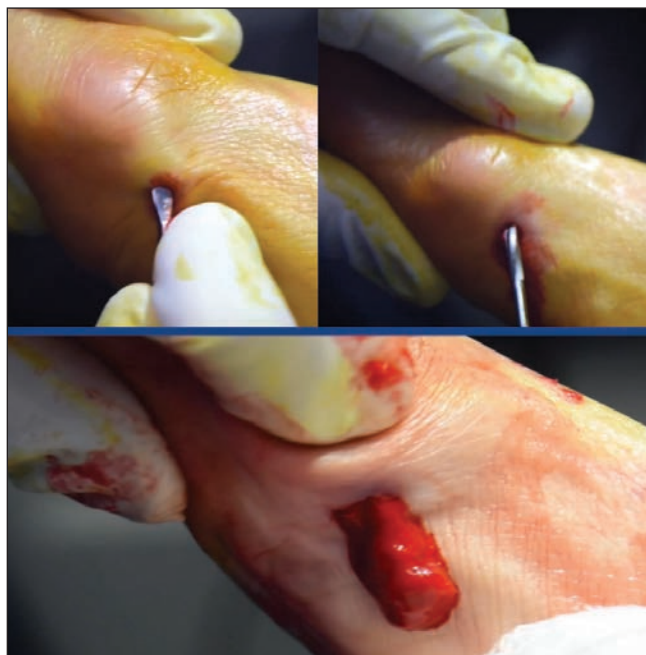

Figure 5: Freeing of capsular structures by Locke elevator and reduction of dorsomedial exostosis using a 3.1 burr. Photo of the dorsal medial exostosis being extracted as bone paste.

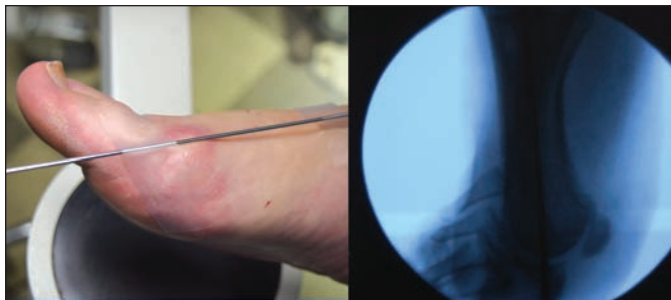

Figure 6: Photo establishing the midline point of the first metatarsal for placement of the pilot hole.

MIAA (from page 108)

ger and Laser Surgery in Podiatry published in 1983 on page 80.⁵ Like the first generation technique, their protocol did not involve internal fixation. The only new aspect of European third-generation HAV MIS procedures is the use of screw fixation. The actual techniques were described and employed by Academy members as early as 1983.

The Fourth Generation

The author will describe a fourth generation technique which differs from the third generation techniques in unique ways. Third-generation techniques involve screw

dial exostosis and a direct approach to correction of frontal plane deformity via rotation of the Akin osteotomy in the frontal plane to better achieve good sesamoid alignment. The fourth generation

MIAA technique combines all the good qualities of the first three generations along with frontal plane correction into one surgical application. The ability to perform the technique in the office setting with less expense is a significant difference between the MIAA and MICA. This may be of interest to USA foot surgeons since it is expected that most insurance companies will soon be reimbursing cost-effective practitioners at a higher rate.

Pre-Operative Criteria

The MIAA procedure is directed at treating symptomatic medial bunion deformities with IM angles up to 17 degrees. The specific cri-

The MIAA Procedure

The MIAA procedure combines several minimally invasive surgical techniques. The technique involves exostectomy of the dorsal medial aspect of the first metatarsal head, a V-shaped distal (Austin) osteotomy at the first metatarsal head, transposition of the metatarsal head laterally, reduction of the medial shelf created by the osteotomy, percutaneous fixation via screws or K-wires, and finally a frontal plane rotational MIS Akin phalangeal osteotomy. The technique outlined below will combine differing cases to help clarify the surgical process and offer differing options for the surgeon.

The MIAA Technique

A .5cm incision is performed with a 64 blade and is made over the plantar medial border of the first ray where the metatarsal head fans

Continued on page 110

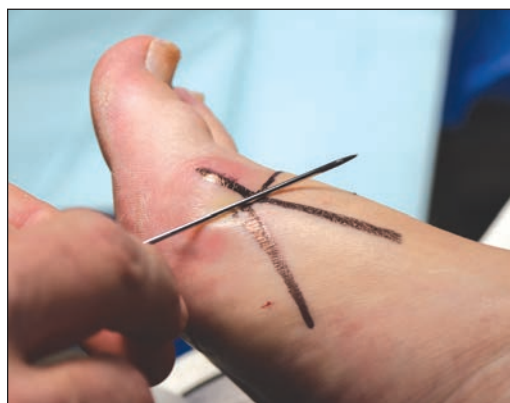

Figure 7: Photo showing the use of external K-wire and the fluoroscopy to draw markers mapping of the pilot hole placement and osteotomy paths.

The MIAA procedure is directed at treating symptomatic medial bunion deformities with IM angles up to 17 degrees.

fixation that require considerable expense. For most foot surgeons, these techniques will be limited to hospital-based and surgery center protocols. The fourth generation MIAA technique described here involves the same time-tested proven osteotomies of the Austin and Akin along with the ability to fixate with K-wires or screws and obtain primary bone healing. The use of K-wires lends itself well to office-based surgery and can be done at a significant reduction in cost compared to the MICA.

The MIAA also differs from the third generation techniques since it allows for removal of the dorsal me-

teria for the MIAA procedure are as follows:

- 1) The first metatarsal phalangeal joint should have good range of motion with no crepitus or pain.
- 2) The first metatarsal phalangeal joint can be congruent, deviated, or subluxed.
- 3) The IM angle should be abnormal up to 17 degrees.
- 4) The PASA is increased.
- 5) DASA angle is normal.
- 6) HA angles are slightly or highly abnormal.
- 7) The relative metatarsal protrusion angle is either positive or negative.

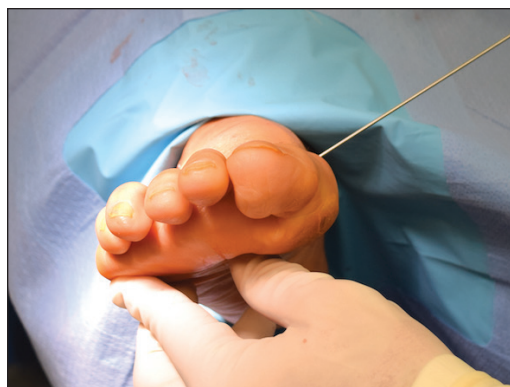

Figure 8: A .062 K-wire used to establish a guide hole for the placement of the straight bur. Note the 20° plantar-flexion angle and the distal orientation towards the third MPJ.

MIAA (from page 109)

out in the distal diaphysis area. The dissection is continued down in a single cut until reaching the periosteum via blunt dissection using a small rasp (Figure 4). From this position, a Locke elevator is used to underscore the capsule at the first metatarsal phalangeal joint, employing a sweeping motion (Figure 5). Under fluoroscopy, a 3.1 wedge burr is inserted and the medial prominence is resected from the first metatarsal head (Figure 5). Pressure is applied to the first metatarsal phalangeal joint area, and the medial eminence is eliminated as bone paste (Figure 5).

The first step of the Austin osteotomy involves performing a pilot hole through which the Austin osteot-

omy will be performed. This is accomplished through an additional .5cm incision. The dorsal plantar outline of the first metatarsal is made by using an externally placed K-wire and the fluoroscope to determine the midpoint of the first metatarsal shaft. This step is normally performed as part of the pre-operative evaluation before surgery begins. The pilot hole for an Austin osteotomy is made over this dorsal plantar mid-point (Figure 6). The second incision is located on the medial aspect of the first metatarsal mid-point with the proximal location at the basal flair of the medial eminence. Skin marks are created using the K-wire held up against the skin as an outline to help in execution of the pilot hole

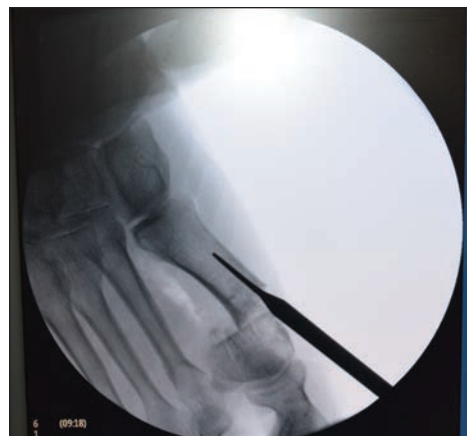

Figure 9: Using the Locke elevator to transposition the metatarsal osteotomy laterally.

direct the osteotomy in a perpendicular orientation to the second metatarsal or more proximally.

After the pilot hole is performed, the dorsal wing of the osteotomy is made and is angled from 0-60 degrees. If the surgeon desires direct PASA correction, a transverse 0° angle for the dorsal wing can be performed with a medial wedge in the Reverdin-Green fashion. For added stability, the dorsal wing can be angled up to 60°. PASA can also be adjusted with the 60-degree dorsal wing after the plantar wing is made by shifting the osteotomy in a medial transverse maneuver as employed in the off-set V performed in conventional techniques. The plantar cut is oriented to achieve a slightly longer plantar limb than the dorsal cut. The author prefers to draw the direction of the osteotomy path utilizing a skin marker and visualization with the fluoroscopy holding the K-wire up to the skin as a guide to mark the skin (Figure 7).

The osteotomy is then shifted laterally by inserting a Locke elevator through the incision site into the medullary canal of the 1st ray, and using this as a fulcrum to transpose the osteotomy (Figure 9). After laterally shifting the osteotomy, a percutaneous lateral release can be done if desired. Thumb pressure can transpose the osteotomy in some patients.

After displacing the osteotomy, temporary fixation is accomplished via percutaneous temporary Steinmann pin placement in a modified

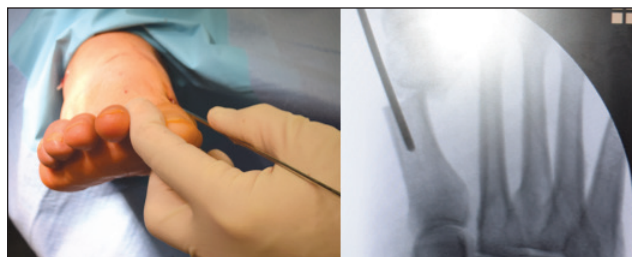


Figure 10: Temporary Steinmann pin fixation by a modified Bosch technique to secure distal fragment in proper position prior to percutaneous fixation.

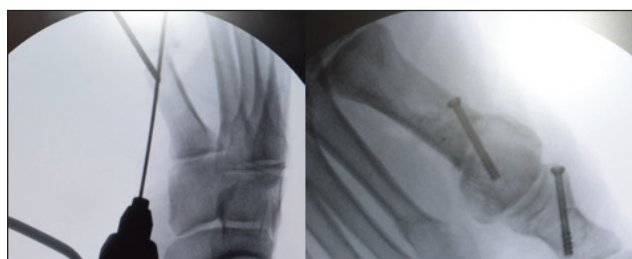


Figure 11: Fixation with either a .062 K-wire or a 3.0 screw from proximal medial to distal lateral.

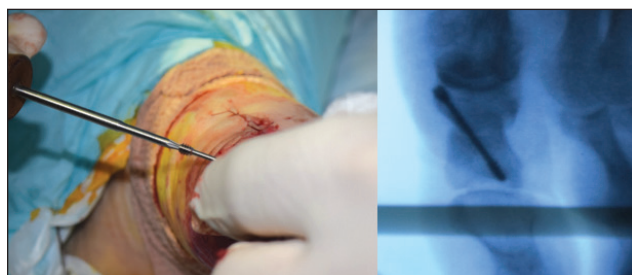


Figure 12: Placement of a percutaneous screw fixation in the Akin osteotomy while holding the distal fragment in an exaggerated varus front plane position. This helps with sesamoid positioning by helping to reduce frontal plane deformity.

and V osteotomy (Figure 7).

The osteotomy pilot hole is performed with a straight burr introduced through this second incision and represents the apex of the Austin cut. The author usually drills a guide hole for the burr using a .062 K-wire (Figure 8). The burr will remove approximately 3 mm of bone. To compensate for potential shortening, the path of the pilot hole is aimed at the third metatarsophalangeal joint and is plantar-flexed 20 degrees (Figure 8). This orientation will counteract the effect the burr has on shortening the first metatarsal. It should be noted that in patients with a long first metatarsal, it may be preferable to

Continued on page 111

MIAA (from page 110)

Bosch version (Figure 10). This temporary fixation technique permits torquing to further close the PASA correction prior to final fixation and helps maintain correction during the percutaneous fixation process. The percutaneous fixation can be performed proximal medial to lateral distal with a .062 K-wire or 3.0 screw (Figure 11). Due to its orientation, the osteotomy will be plantar-flexed and will maintain the 1st metatarsal length following the fixation. The medial shelf created by the osteotomy is reduced using the same plantar medial incision used to remove the medial eminence with a small rasp and straight bur. The Akin osteotomy is performed next.

The Percutaneous MIS Akin

An incision is made using a 64 blade over the medial aspect of the proximal phalanx great toe and car-

ried down to the periosteum structures with a small rasp. A small rasp is introduced and used to remove the periosteum from the medial aspect of the phalanx and the dorsal aspect in the path in which the cut-

aspect of the hallux with the lateral cortex intact.

If frontal plane correction is needed, this cut is made through and through, and the hallux is held in varus position prior to fixation,

The first step of the Austin osteotomy involves performing a pilot hole through which the Austin osteotomy will be performed.

ting burr edge will be traveling. A straight bur is then inserted between the bone and the reflected periosteum. A precise placement is required to avoid damage to adjacent neurovascular structures. The osteotomy is performed perpendicular to the axis of the proximal phalanx. Once the osteotomy is begun by the rotary burr, a reciprocating motion is made performing an osteotomy in the medial

which helps rotate the sesamoids under the first metatarsal. By applying pressure to the toe medially while maintaining the oscillating movement, the desired wedge can be removed. Lastly, the osteotomy is closed by forcible closure and fixated with cross K-wire fixation or 3.0 screw insertion. If frontal plane correction is required, the distal frag-

Continued on page 112



MIAA (from page 111)

ment is held in varus rotation prior to fixation (Figure 12).

All steps of the procedure should be directly monitored under fluoroscopy guidance to ensure correct placement of incisions, osteotomy angles, appropriate IM closure, proper fixation placement, and adequate bunion prominence removal, etc. The procedure should be performed in a sterile environment, with the patient prepped and draped in the usual sterile manner.

Precautions

MIS foot surgery is changing several protocols as more research and implementation of these techniques are performed. This does not decrease the in-depth theoretical and practical familiarity with medical and surgical foot disorders that a foot surgeon must possess. MIS techniques should be used only by experienced surgeons who regularly perform procedures on the foot. This will allow the ability to select the best treat-

ment option on a case-by-case basis. MIS surgery is not intended to supersede conventional surgery but should instead be integrated within the full array of treatment options.

Advantages and Disadvantages of MIS Foot Surgery

MIS bunion surgery has some inborn advantages. These advantages include shorter operative times, less scarring, and potential for better patient satisfaction as compared to conventional surgical correction. The most obvious disadvantages are the need for specific equipment, including fluoroscopy. This requires a significant financial commitment. In addition, the learning curve is steep. The author recommends participating in cadaver labs like the seminars given by the AAFAS where experienced MIS surgeons are available to teach these techniques.

Conclusion

The available literature on third generation MIS bunion correction suggest that MIS HAV correction is a safe and reliable technique. It provides comparable correction with no increase in complication compared with open techniques. The fourth-generation technique described by the author uses the same basic principles as the third-generation techniques. It is the intention of the author to compare the conventional Austin/Akin bunion correction to the MIAA. For most of the author's career, he has implemented HAV correction by conventional techniques. He intends to report a comparative result achieved with respect to the use of the conventional Austin/Akin and its MIS version for the correction of HAV. By having this study implemented by the same surgeon, a

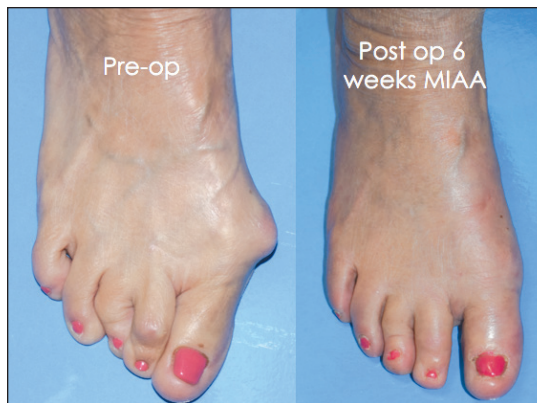
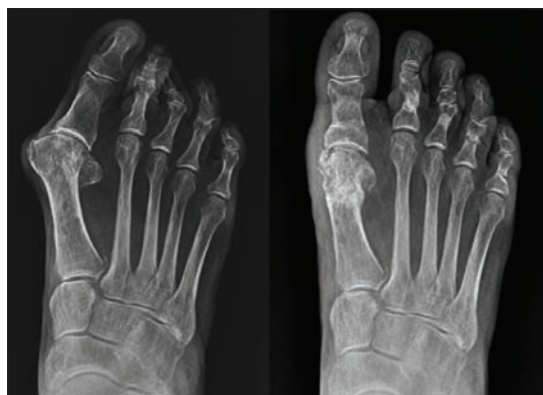

Figure 13: Six-week post-op result of MIAA bunion correction performed in the office with .062 K-wire fixation.

level 2 presentation can be reported soon. Figure 13 represents a pre-op and post-op eight weeks MIAA procedure performed in the office under local anesthesia using .062 K-wire fixation. The pre-op weight-bearing AP and lateral views and post-op, eight-week, weight-bearing AP and lateral views are shown in Figures 14 and 15 for the patient shown in Figure 13. **PM**

References

- ¹ Maffulli N, Easley M. Minimally Invasive Surgery of the Foot and Ankle 2011: 97.
- ² Isham S. The Reverdin-Isham procedure for HAV: Clin Pod Med Surg 1991;8: 81-94.
- ³ Bosch P, Wanke S, Legenstein R. Hallux valgus correction by method of the Bosch: A new method 7-10 year follow-up Foot Ankle Clin 2000; 5: 485-98.
- ⁴ Lam P, et al. Percutaneous Surgery for Mild to Moderate Hallux Valgus: Foot and Ankle Clinics 2016;21: 459-477.
- ⁵ Gorman J, Plon M. Minimal Incision Surgery and Laser Surgery in Podiatry 1983.



Figures 14: Weight-bearing pre-op AP and post-op weight-bearing AP views for the patient depicted in Figure 13.

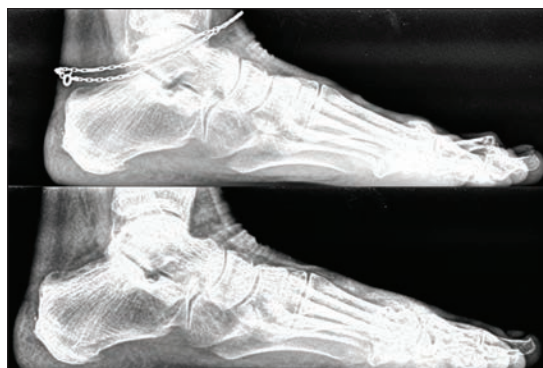

Figure 15: Pre-op and eight week post-op lateral weight-bearing views for the patient depicted in Figure 13.



Dr. Peacock has been in private practice for 18 years in Whiteville, NC. He was traditionally trained in a podiatric surgical residency. He is an assistant professor in the AAFAS (Academy of Ambulatory Foot and Ankle Surgery) and is a

diplomat of the American Board of Podiatric Surgery (ABPS). Dr. Peacock has an interest in expanding the scope and acceptance of MIS foot surgery in the podiatric medical community. He believes that MIS procedures can be used as a valuable part of a traditional foot surgeon's arsenal of tools.