



# Radiographic Fundamentals Review

The author discusses imaging methods, exposure factors, and patient positioning.

BY ALBERT ARMSTRONG, DPM

## Objectives

After completion of this CME, the reader will:

- 1) Recognize which imaging modality to order for the evaluation of cortical bone.
- 2) Recognize which nuclear medicine study to order to evaluate for stress fractures.
- 3) Recognize which nuclear medicine study to order to evaluate osteomyelitis in children versus adults.
- 4) Recognize when to order a nuclear medicine bone marrow scan.
- 5) Recognize the imaging method of choice for radiolucent soft tissue foreign bodies.
- 6) Recognize the imaging method of choice for acute osteomyelitis.
- 7) Recognize the imaging method of choice for soft tissue tumors.
- 8) Recognize how to adjust exposure factors when a radiograph is over or under exposed.
- 9) Recognize how to adjust exposure factors when evaluating soft tissues on radiographs.
- 10) Recognize how to position for isolated lateral digits.
- 11) Recognize how to position the lateral heel for a foreign body.
- 12) Recognize how to position for medial column or lateral column radiographs by moving the x-ray tube or the patient.
- 13) Recognize how to position and adjust exposure factors for a sesamoid axial view.
- 14) Recognize how to position a patient for a proximal tibia and fibula.

Welcome to Podiatry Management's CME Instructional program. Podiatry Management Magazine is approved by the Council on Podiatric Medical Education as a provider of continuing education in podiatric medicine. Podiatry Management Magazine has approved this activity for a maximum of 1.5 continuing education contact hours. This CME activity is free from commercial bias and is under the overall management of Podiatry Management Magazine.

You may enroll: 1) on a per issue basis (at \$33.00 per topic) or 2) per year, for the special rate of \$279 (you save \$51). You may submit the answer sheet, along with the other information requested, via mail, fax, or phone. You can also take this and other exams on the Internet at [podiatrym.com/cme](http://podiatrym.com/cme).

If you correctly answer seventy (70%) of the questions correctly, you will receive a certificate attesting to your earned credits. You will also receive a record of any incorrectly answered questions. If you score less than 70%, you can retake the test at no additional cost. Other than those entities currently accepting CPME-approved credit, Podiatry Management cannot guarantee that these CME credits will be acceptable by any state licensing agency, hospital, managed care organization or other entity. PM will, however, use its best efforts to ensure the widest acceptance of this program possible.

**This instructional CME program is designed to supplement, NOT replace, existing CME seminars.** The goal of this program is to advance the knowledge of practicing podiatrists. We will endeavor to publish high quality manuscripts by noted authors and researchers. If you have any questions or comments about this program, you can e-mail us at [bblock@podiatrym.com](mailto:bblock@podiatrym.com).

Following this article, an answer sheet and full set of instructions are provided.—**Editor**

**T**his article is a review of radiographic exposure factors and some of the less common positioning techniques. But first, a review of the most commonly ordered imaging modalities (plain film radi-

ography and CT, nuclear medicine, diagnostic medical ultrasound, and MRI) and which imaging modalities to order when.

### Plain Film Radiography and CT

Plain film radiography and com-

puterized tomography (CT) are best for cortical bone. So for bone trauma, or bone pathology of any kind, plain film radiography is indicated.<sup>1</sup> If plain film radiographs are equivocal, or if further evaluation is needed for bone tumors, coalitions, or intra-articular

fractures, CT without contrast (or CT plain) is indicated. Remember that plain film radiography and CT are the same imaging modality. With CT, there is an x-ray tube in the gantry, which moves circumferentially around the patient. The results are x-ray tomograms, or x-ray “slices”. The images are evaluated in the same manner as plain film radiographs. The hospital CT machines have a thinly collimated fan x-ray beam. This results in superior contrast resolution compared to plain film radiography. With this type of scanner, the x-ray tube moves circumferentially around the patient several times in order to image a volume of tissue. There is a new weight-bearing CT scanner that is appropriate

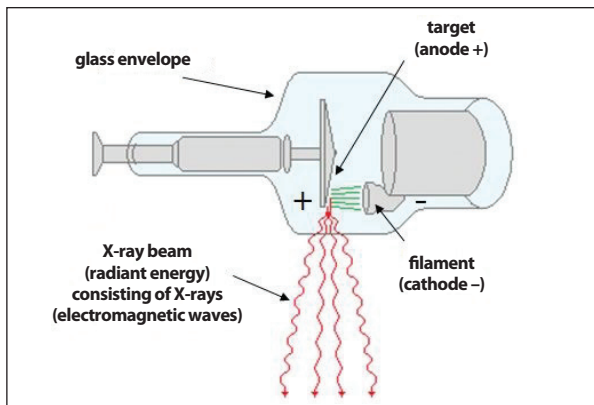


Figure 1: Schematic of an x-ray tube showing the cathode, which houses the filament. This is where the electrons are produced. Also shown is the anode, where the electron beam hits. The mAs controls the amount (or quantity) of electrons produced, and the kVp controls the force with which the electron beam hits the anode target.

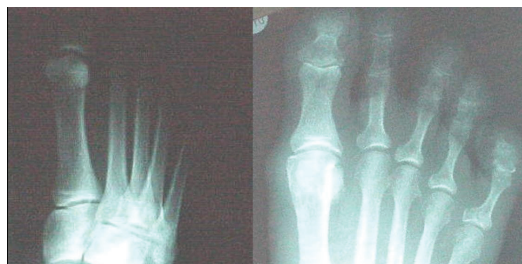

Figure 2: Radiograph of the forefoot using 58 kVp (left). The digits and soft tissue are overexposed. In the radiograph of the digits using 54 kVp (right), the digits now have the correct exposure for medical evaluation. The alignment, bone density, cortical margins, and some soft tissue can be seen.

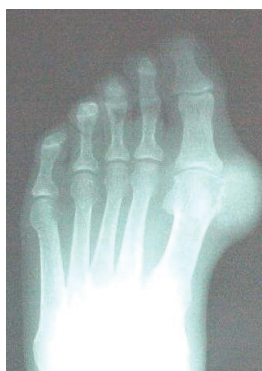

Figure 3: Radiograph of the foot to evaluate soft tissue. The kVp was decreased to 50. The radiograph is of a patient with a history of gout. With the low kVp exposure technique, the gouty tophus can be seen medial to the first metatarsophalangeal joint, with increased soft tissue density.

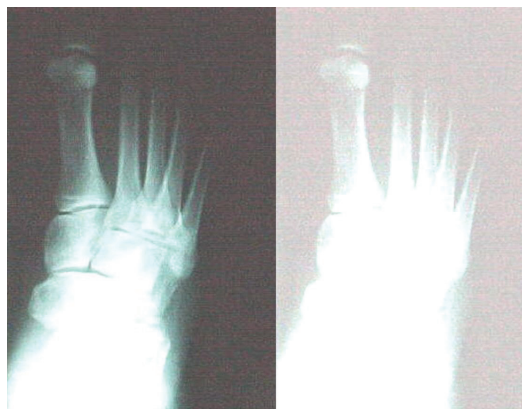


Figure 4: Radiograph of the forefoot using 58 kVp (left). The digits and soft tissue are overexposed. Imaging software was used to make the image lighter (right). However, even though the image is lighter, the digits and soft tissue are still overexposed. The kVp is too high to evaluate the digits or soft tissue, and imaging software cannot compensate for this fact.

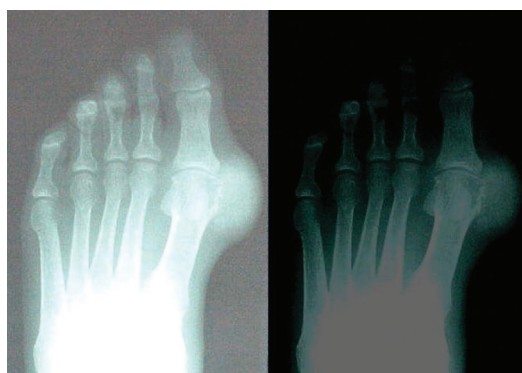


Figure 5: Radiograph of the forefoot using 50 kVp (left). The bases of the metatarsals and the cuneiforms are underexposed. Imaging software was used to make the image darker (right). However, even though the image is darker, the bases of the metatarsals and cuneiforms are still underexposed. The kVp is too low to evaluate that area, and imaging software cannot compensate for this fact.

for a physician’s office. This type of scanner uses a cone-shaped x-ray beam. The advantage of this is that a volume of tissue can be imaged in one circumferential pass around the patient.

### Nuclear Medicine Modalities

Nuclear medicine modalities include the <sup>99m</sup>Tc MDP single phase bone scan, the <sup>99m</sup>Tc MDP triple phase bone scan, the <sup>111</sup>In-WBC scan, the Ceretek (<sup>99m</sup>Tc HMPAO [Hexamethylpropylamine-oxime]) scan, and the <sup>99m</sup>Tc Sulfur colloid bone marrow scan. The <sup>99m</sup>Tc MDP single phase bone scan is used for any process that results in increased osteoblastic activity. Suspected stress fractures that do not appear on plain film radiographs can be imaged with the

## CT plain should be ordered to evaluate intra-articular calcaneal fractures.

single phase bone scan. The <sup>99m</sup>Tc MDP triple phase bone scan was developed to increase the specificity of bone scanning for osteomyelitis (to distinguish osteomyelitis from cellulitis). In the first phase of a triple phase bone scan, the patient is imaged immediately post-injection, every 3 to 6 seconds. Information is obtained about the relative blood supply of the area being imaged.

The second phase, called the “blood pool” phase, is also known as the tis-

sue phase. This image is obtained 5 minutes post-injection. It quantifies the relative hyperemia or ischemia of the area being imaged. The third phase is called the delayed phase. The image is obtained 3 to 4 hours post-injection. It demonstrates the regional rates of bone metabolism.

Ceretec scan is recommended for osteomyelitis in children. The patients can be imaged 2 and 4 hours post-injection. The radiation dose is lower than that with the <sup>111</sup>In-WBC scan.<sup>3</sup> The <sup>99m</sup>Tc sulfur colloid bone marrow scan is usually done to supplement a labeled white blood cell scan when

echogenicity, and neovascularization. Diagnostic medical ultrasound increases the success rate of nerve blocks in the lower extremity.<sup>5</sup> In addition, ultrasound has emerged as the imaging method of choice for the localization of radiolucent soft tissue foreign bodies.<sup>6</sup>

MRI is what to order for acute osteomyelitis, soft tissue tumors, and bone contusions (after plain radiographs). Remember, for soft tissue tumors, order MRI with contrast. The reason for this is to see if there is a vascular supply to the tumor. Although MRI is the imaging method of choice for acute osteomyelitis, chronic osteomyelitis and an active Charcot joint should be imaged with a white blood cell labelled scan.

**<sup>99m</sup>Tc MDP single phase bone scan is preferred to evaluate for stress fractures.**

Sometimes, a fourth phase is done. This image is taken 24 hours post-injection. It increases the specificity for osteomyelitis.<sup>2</sup> The leukocyte tagged nuclear medicine scans (the <sup>111</sup>In-WBC scan, the Ceretec [<sup>99m</sup>Tc HMPAO [Hexamethylpropylamine-oxime]]) further increase the specificity for infection imaging. The <sup>111</sup>In-WBC scan is recommended for osteomyelitis in adults. Patients can be scanned at 3 and 24 hours post-injection.

Because musculoskeletal infection, especially with orthopedic implants, is often low grade and chronic in nature, the <sup>111</sup>In-WBC scan is preferred over the Ceretec scan, as it allows more time for the leukocytes to migrate to the site of infection. The

looking for infection in bones and joints, especially when the patient has had recent surgery or trauma to the area in question. Impacted bone can show as increased uptake on a white blood cell labelled scan even when infection is not present. In a case such as this, the <sup>99m</sup>Tc sulfur colloid bone marrow is done in conjunction with the Ceretec scan. If the bone marrow scan shows increased uptake as well as the white blood cell labelled scan, then infection is not present. In other words, a hot white blood cell labelled scan and a hot bone marrow scan is not infection.

**Diagnostic Ultrasound**

For musculoskeletal diagnostic medical ultrasound in the physician's office, one should use a linear array transducer, 10 MHz or above. Remember, increasing the frequency of sound increases the resolution but decreases the depth. This is ideal for foot and ankle imaging since most of the anatomic structures are relatively superficial. The advantages of ultrasound over MRI when evaluating soft tissue include: the ability to do guided aspiration of cystic lesions, guided injections, and foreign body localization and removal. The images are in real time, and one can take anatomic cuts in virtually any plane. Further, one can do dynamic imaging. For example, the patient can be put through a range of motion to image a dislocated tendon, which cannot be done with MRI.

Ultrasound is a valuable imaging modality for tendon pathology.<sup>4</sup> Tendons can be evaluated for shape,

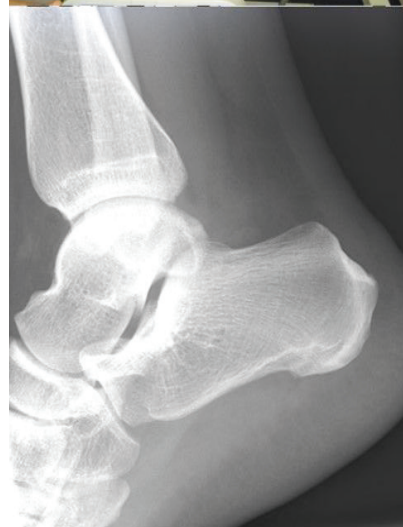
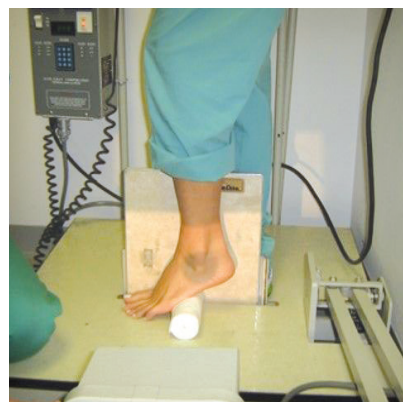
Figure 7: Positioning for soft tissue heel for foreign body (top), and the resultant radiograph (bottom). Cast padding is placed under the midfoot so that the soft tissue of the heel is in the air. If one is looking for a foreign body in the plantar soft tissue more anteriorly, the heel can be placed down on the platform, and the forefoot would be in the air.

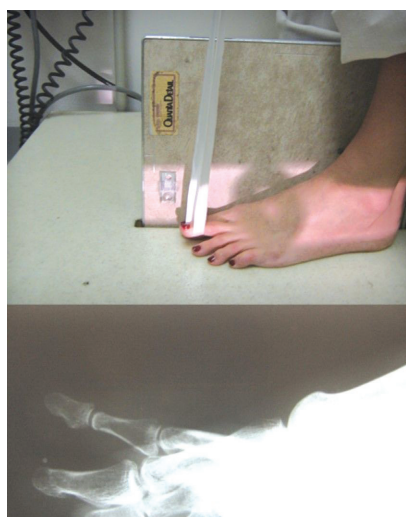

Figure 6: Positioning for an isolated lateral digit using a folded piece of silk tape (top), and the resultant radiograph (bottom). Since a lower kVp was used for the single digit, the area of the metatarsals is underexposed. This is acceptable if we are only interested in the digit.



Radiography, by definition, is using the x-ray beam, and its ability or inability to penetrate different types of tissues to produce an image to aid in the diagnosis and treatment of injury or disease.<sup>7</sup> Radiopaque structures appear white, radiolucent structures appear black, and other structures appear as different shades of gray. When film is exposed, it turns black. An overexposed image will appear too black, and an underexposed will appear too white. Recall that the primary exposure factors are the milliamperes (or the mA), the kilovolt peak (or the kVp) and the time

in seconds, (or s). The exposure factors can be manipulated to influence the quantity and the quality of the

cathode side of the x-ray tube when one presses the exposure button.<sup>8</sup> The mA controls the amount of

**If a radiograph is too black, the radiograph is overexposed, and the exposure factors need to be decreased.**

radiation coming out of the x-ray tube (Figure 1).

**The Quantity of Radiation**

Electrons are formed on the

current going to the filament on the cathode side of the tube. The higher the current, the more electrons will be produced. The electrons will travel across the x-ray

tube and bombard the anode target. The collision of the electrons with the anode target produces x-radiation. Therefore, the more electrons, the more radiation. A lower mA will produce fewer electrons, and therefore, less radiation. The mA controls the quantity of radiation coming out of the x-ray tube. The time (s), on the other hand, also controls the quantity of radiation coming out of the x-ray tube, but in a different way. The timer on the control panel controls the amount of time the current is applied to the filament on the cathode side of the tube. The longer the time the current is applied to the filament, the more electrons will be produced. Again, more electrons produced means more electrons will hit the anode target. More electrons hitting the anode means more radiation will be produced. Therefore, the mA and the time control the amount, or

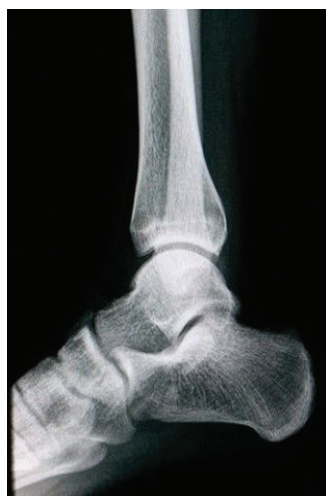

Figure 8a: Lateral ankle radiograph. The kVp is too high to identify the structures delineating Kager's triangle.

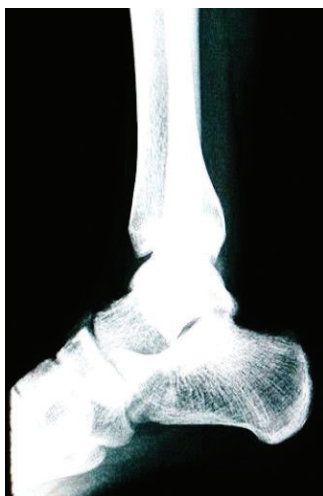

Figure 8b: Same radiograph as in 8a. Computer software was used to lighten the radiograph. However, the structures delineating Kager's triangle still cannot be identified, because the kVp was too high. The image is overexposed to evaluate soft tissue.

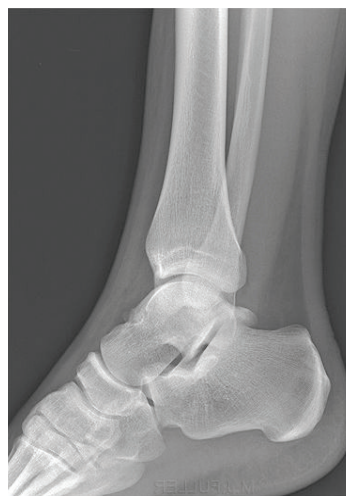

Figure 8c: Lateral ankle radiograph using a lower kVp exposure technique than the radiograph in 8a. The structures delineating Kager's triangle and Kager's fat pad can be identified.

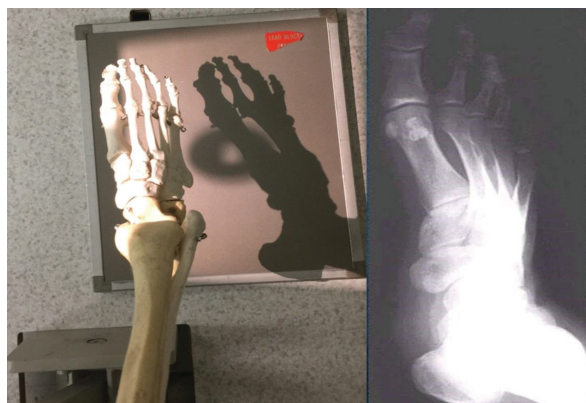


Figure 9a: The left image shows the foot model with the lateral side down and the resultant shadow. In comparison, the oblique radiograph of the foot is with the lateral side down, and the resulting radiograph is similar to the shadow.

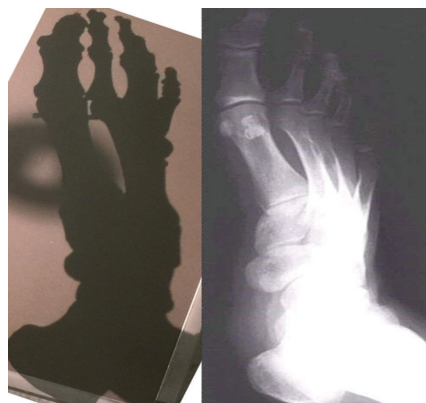

Figure 9b: A close-up of the shadow of a foot model and the radiograph, lateral side down, similarly showing the medial column.

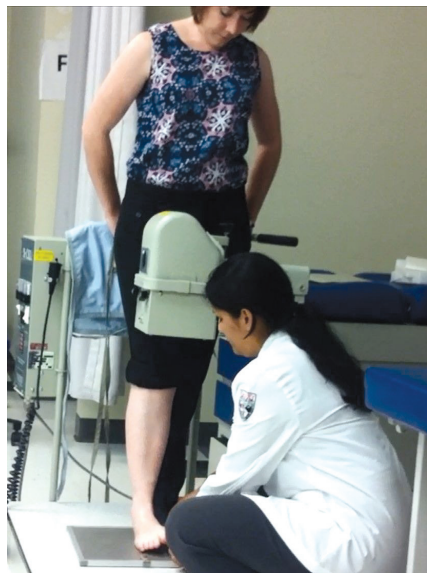

Figure 9c: Positioning for a medial column radiograph, angling the patient's foot.

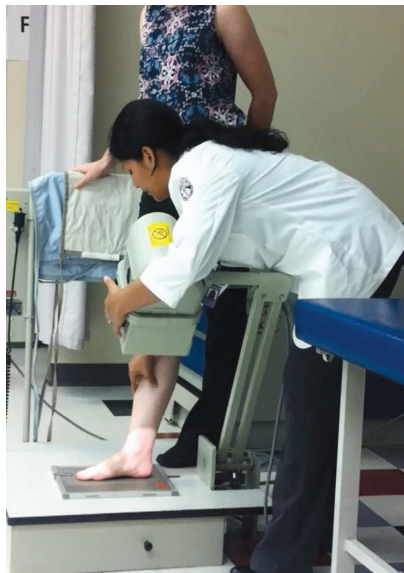

Figure 9d: Positioning for a medial column radiograph, angling the x-ray tube.

quantity, of radiation coming out of the x-ray tube.

**Quality of the X-ray Beam**

There is a difference in potential between the negative cathode and positive anode. Raising the kilovolt peak, or kVp, will increase the difference in potential across the x-ray tube. In other words, raising the kVp will increase the negativity of the cathode and the positivity of the anode. This will cause the electrons to hit the anode with a much greater force. The result will be an x-ray beam with a greater penetrating power. Turning the kVp down will have the opposite effect: an x-ray beam will be produced that has a lower penetrating power. A low kVp technique is better for evaluating soft tissue. This is why a very low kVp is required for mammography.<sup>9</sup>

**Adjusting the Exposure Factors**

If one wants the image to appear darker, the exposure factors need to be increased, whether it is the mA, the time, or the kVp. If one wants the image to appear lighter, the exposure factors would need to be decreased, whether it is the mA, time, or kVp. One way to adjust exposure factors to compensate

for an overexposed or underexposed radiograph is to adjust the kVp by 4. For example, 58 kVp was used for the radiograph for the midfoot in Figure 1. The digits, however, are overexposed. When decreasing the kVp to 54, the digits can now be seen (Figure 1). If one desires an even lighter radiograph to evaluate soft tissue, the kVp can be decreased by 4 more, bringing it to 50 kVp (Figure 2). With the advent of digital imaging, there is an ability to manipulate a radiograph with software if it is overexposed or underexposed.

However, this is only possible in a narrow range. If a radiograph is too overexposed, imaging software will not compensate for this (Figure 3). Similarly, if a radiograph is too underexposed, imaging software will not compensate for this either (Figure 4).

When needing to evaluate soft tissues on radiographs, one should use a low kVp, similar to that of mammography. This may be necessary for foreign body localization, or for evaluating gas in the tissues. When evaluating the digits for foreign bodies, an isolated lateral radiograph is useful. This positioning technique will free the digit from superimposition of the other digits. Since we are only interested in a single digit, the kVp can be lowered by 4 from what is used for a

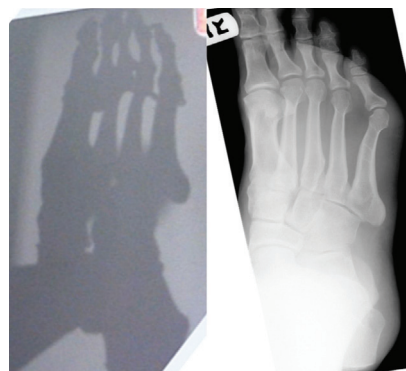

Figure 10a: A close-up of the shadow and the radiograph, medial side down, similarly showing the lateral column.

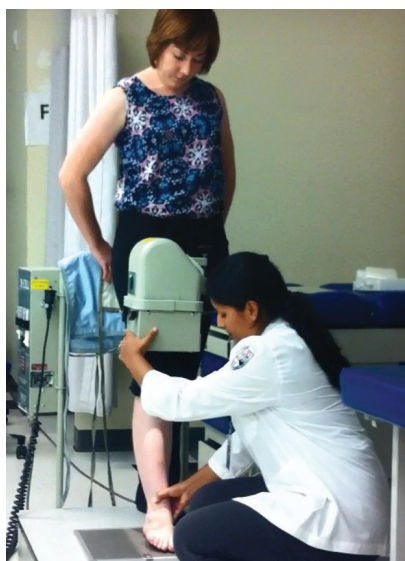

Figure 10b: Positioning for a lateral column radiograph, angling the patient's foot.

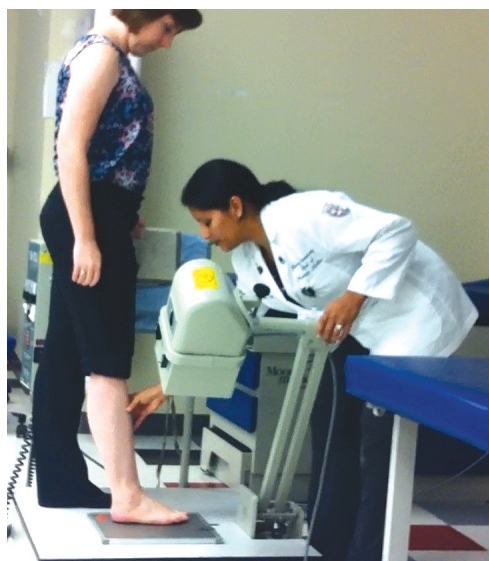

Figure 10c: Positioning for a lateral column radiograph, angling the x-ray tube.



complete foot radiograph (Figure 6.) In addition, one should always use the smallest exposure field possible to reduce patient exposure and scatter radiation. For radiographs of the heel when looking for a soft tissue foreign body, the patient does not need to be weight-bearing. Therefore, the heel can be elevated (e.g., with cast padding), so that the soft tissue is not obscured (Figure 6). One should remember that diagnostic medical ultrasound has emerged as the imaging method of choice for radiolucent soft tissue foreign bodies.

### Kager's Triangle

Kager's triangle and Kager's fat pad can be used to evaluate pathology of the posterior ankle, such as edema, infection, hemorrhage, inflammation, neoplasm, tendonitis, and Achilles tendon rupture. However, if the kVp is too high, Kager's triangle won't be visible (Figure 8a). Even if computer software is used to make the image lighter, Kager's tri-

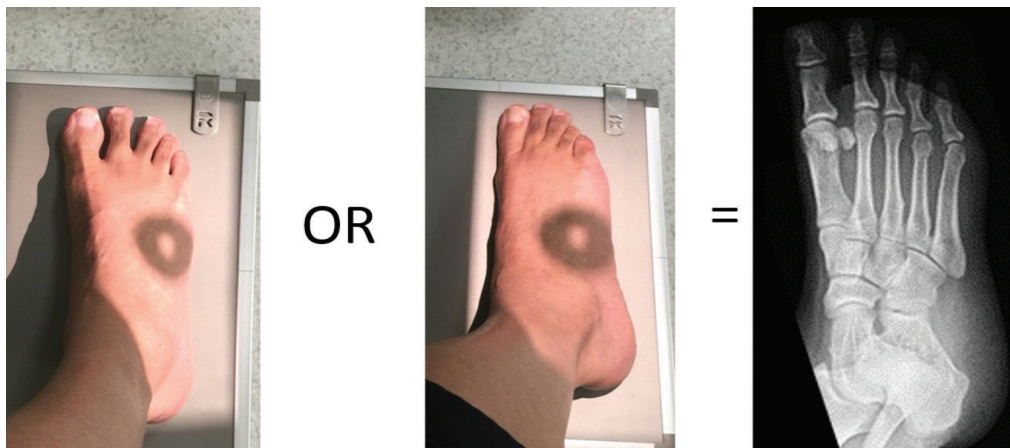


Figure 10d: Angling the foot or angling the x-ray tube in the above manner will result in the lateral column radiograph. Note that whether angling the foot or the x-ray tube, the central ray is in the same area on the foot.

angle can't be identified because the image is still overexposed (Figure 8b). If the kVp is low enough, the structures delineating Kager's triangle can be identified (Figure 8c).

There is some confusion over the terminology concerning medial oblique radiographs and lateral oblique radiographs. With oblique radiographs, one should remember that the images are basically shadows, and they behave like shadows. When taking an oblique radiograph with the lateral side of the foot down closest to the cassette, one can see the medial column with little superimposition (Figure 9a).

A shadow of a skeleton model with the lateral side down, and the actual radiograph of the foot with the lateral side down, are similar images (Figure 9b). There are two different maneuvers that can produce the medial column radiograph. One can have the patient angle the foot (Figure 9c), or one can angle the x-ray tube (Figure 9d).

When taking an oblique radiograph with the medial side of the foot down closest to the cassette, one can see the lateral column, cuboid, and fifth metatarsal base and styloid process with little superimposition. The shadow of the

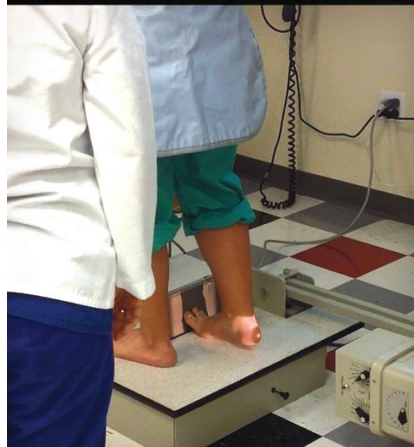

Figure 11: Sesamoid axial radiograph and positioning.

## Diagnostic ultrasound modality has emerged as the imaging method of choice for radiolucent soft tissue foreign bodies.

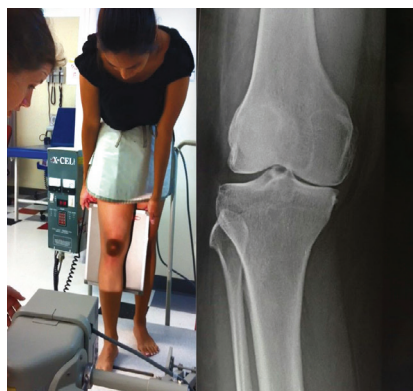

Figure 12a: Positioning for the AP proximal tibia and fibula and resulting radiograph.

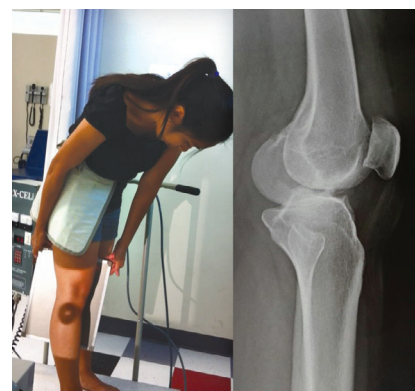

Figure 12b: Positioning for the lateral proximal tibia and fibula and resulting radiograph.

skeleton model and the actual radiograph of the foot are similar images (Figure 10a). There are two different maneuvers that can produce the lateral column radiograph. One can have the patient angle the foot (Figure 10b), or one can angle the x-ray tube (Figure 10c).

When performing the sesamoid axial, one can use the same exposure factors as used for the calcaneal axial, with the kVp increased by 4 (Figure 11).

When there is a need to take radiographs of the proximal tibia and fibula, one can do this by having the patient hold the cassette. For the AP proximal tibia and fibula, one should shield the patient first, before positioning. Then, have the patient hold the cassette behind the knee (Figure 12a). For the lateral radiograph of the proximal tibia and fibula, have the patient hold the cassette between the legs (Figure 12b). One can use the same expo-

sure factors used for the ankle, with the kVp increased by 4. **PM**

### References

- <sup>1</sup> Manaster, B.J., May, D.A., Disler, D.G. (2007) *Musculoskeletal Imaging: The Requisites*, Third Edition. Philadelphia, Mosby.
- <sup>2</sup> Crim JR. (1996). *Imaging of the Foot and Ankle*. London, Lippincott-Raven.
- <sup>3</sup> Resnick, D., Kransdorf, M. (2004). *Bone and Joint Imaging*, Third Edition. Philadelphia, Elsevier Saunders.
- <sup>4</sup> Jacobson, JA. (2007). *Fundamentals of Musculoskeletal Ultrasound*. Philadelphia, Saunders-Elsevier.
- <sup>5</sup> Redborg, K., et al. (2009). Ultrasound Improves the Success Rate of a Sural Nerve Block at the Ankle. *American Society of Regional Anesthesia and Pain Medicine*.
- <sup>6</sup> Adler, R., Sofka, C., Positano, R. (2004). *Atlas of Foot and Ankle Sonography*. Philadelphia, Lippincott Williams & Wilkins.
- <sup>7</sup> Armstrong, A. (2010). *Radiation Safety and Training Manual for Fixed Length Podiatric Radiography Equipment*.

Florida Podiatric Medical Association.

<sup>8</sup> Bushong, S. (2012) *Radiologic Science for Technologists*, 10th edition. St. Louis, Mosby.

<sup>9</sup> Novelline, RA. *Squire's Fundamentals of Radiology Sixth Edition*. (Harvard: Cambridge, 2004).



**Dr. Armstrong** attended the University of Colorado in Boulder, and Midwestern State University in Texas, where he received a Bachelor of Science in radiology. He spent eight years in the United States Air Force, where he worked as a radiology technologist, CT technologist, interventional technologist, and radiology quality control officer. He received a Master of Science Degree in Biomedical Sciences, and Doctor of Podiatric Medicine from Barry University and did his residency at Mount Sinai Medical center in Miami Beach, FL, and a CT fellowship at Thomas Jefferson University Hospital in Philadelphia, PA. He is Professor of Radiology and past Dean at Barry University School of Podiatric Medicine.

## CME EXAMINATION

1) What is the imaging method of choice to evaluate cortical bone pathology after plain film radiography?

- A) MRI
- B) Diagnostic ultrasound
- C) Nuclear medicine
- D) CT

2) What imaging modality should be ordered to evaluate intra-articular calcaneal fractures?

- A) MRI plain
- B) MRI with contrast
- C) CT plain
- D) CT with contrast

3) Which nuclear medicine study is preferred to evaluate for stress fractures?

- A) <sup>99m</sup>Tc MDP single phase bone scan
- B) <sup>99m</sup>Tc MDP triple phase bone scan
- C) <sup>111</sup>In-WBC scan.
- D) <sup>99m</sup>Tc Sulfur colloid bone marrow scan

4) Which nuclear medicine study is preferred to evaluate osteomyelitis in children?

- A) Ceretec (<sup>99m</sup>Tc HMPAO [Hexamethylpropylamine-oxime}) scan
- B) <sup>99m</sup>Tc MDP single phase bone scan
- C) <sup>99m</sup>Tc MDP triple phase bone scan
- D) <sup>111</sup>In-WBC scan.

5) Which nuclear medicine study is preferred to differentiate between osteomyelitis and bone impaction?

- A) <sup>99m</sup>Tc MDP single phase bone scan
- B) <sup>99m</sup>Tc MDP triple phase bone scan
- C) Ceretec (<sup>99m</sup>Tc HMPAO [Hexamethylpropylamine-oxime}) scan
- D) <sup>99m</sup>Tc Sulfur colloid bone marrow scan in conjunction with a <sup>111</sup>In-WBC scan

6) Which imaging modality is the gold standard for evaluating acute osteomyelitis?

- A) CT
- B) Nuclear medicine
- C) Diagnostic ultrasound
- D) MRI

- 7) Which imaging modality should be ordered to evaluate a soft tissue tumor?
- A) CT plain
  - B) CT with contrast
  - C) MRI
  - D) MRI with contrast
- 8) Which imaging modality has emerged as the imaging method of choice for radiolucent soft tissue foreign bodies?
- A) CT
  - B) MRI
  - C) Diagnostic ultrasound
  - D) Plain film radiography
- 9) If a radiograph is too black, how do the exposure factors need to be adjusted?
- A) The radiograph is overexposed, and the exposure factors need to be decreased.
  - B) The radiograph is overexposed, and the exposure factors need to be increased.
  - C) The radiograph is underexposed, and the exposure factors need to be decreased.
  - D) The radiograph is underexposed, and the exposure factors need to be increased.
- 10) If 10mA .1s and 70kVp is used for a radiograph, and one wanted to see more soft tissue, how do the exposure factors need to be adjusted?
- A) Double the mA
  - B) Double the time
  - C) Increase kVp
  - D) Decrease the kVp

The author(s) certify that they have NO affiliations with or involvement in any organization or entity with any financial interest (such as honoraria; educational grants; participation in speakers' bureaus; membership, employment, consultancies, stock ownership, or other equity interest), or non-financial interest (such as personal or professional relationships, affiliations, knowledge, or beliefs) in the subject matter or materials discussed in this manuscript.

## PM's CME Program

Welcome to the innovative Continuing Education Program brought to you by *Podiatry Management Magazine*. Our journal has been approved as a sponsor of Continuing Medical Education by the Council on Podiatric Medical Education.

### Now it's even easier and more convenient to enroll in PM's CE program!

You can now enroll at any time during the year and submit eligible exams at any time during your enrollment period.

**CME articles and examination questions from past issues of *Podiatry Management* can be found on the Internet at [podiatrym.com/cme](http://podiatrym.com/cme).** Each lesson is approved for 1.5 hours continuing education contact hours. Please read the testing, grading and payment instructions to decide which method of participation is best for you.

Please call 718-897-9700 if you have any questions. A personal operator will be happy to assist you.

Each of the 10 lessons will count as 1.5 credits; thus a maximum of 15 CME credits may be earned during any 12-month period. You may select any 10 in a 24-month period.

***The Podiatry Management Magazine CME Program is approved by the Council on Podiatric Medical Education as a provider of continuing education in podiatric medicine. Podiatry Management Magazine CME has approved this activity for a maximum of 1.5 Continuing Education Contact Hours for each exam successfully completed.***

PM's privacy policy can be found at [podiatrym.com/privacy.cfm](http://podiatrym.com/privacy.cfm).

This CME is valid for CPME-approved credits for three (3) years from the date of publication.



# Enrollment/Testing Information and Answer Sheet

**Note:** If you are mailing your answer sheet, you must complete all info. on the front and back of this page and mail with your credit card information to: **Program Management Services, 12 Bayberry Street, Hopewell Junction, NY 12533.**

## TESTING, GRADING AND PAYMENT INSTRUCTIONS

(1) Each participant achieving a passing grade of 70% or higher on any examination will receive an official computer form stating the number of CE credits earned. This form should be safeguarded and may be used as documentation of credits earned.

(2) Participants receiving a failing grade on any exam will be notified and permitted to take one re-examination at no extra cost.

(3) All answers should be recorded on the answer form below. For each question, decide which choice is the best answer, and circle the letter representing your choice.

(4) Complete all other information on the front and back of this page.

(5) Choose one out of the 3 options for testgrading: mail-in, fax, or phone. To select the type of service that best suits your needs, please read the following section, "Test Grading Options".

## TEST GRADING OPTIONS

### Mail-In Grading

To receive your CME certificate, complete all information and mail with your credit card information to: **Program Management Services, 12 Bayberry Street, Hopewell Junction, NY 12533.**

**PLEASE DO NOT SEND WITH SIGNATURE REQUIRED, AS THESE WILL NOT BE ACCEPTED.**

There is **no charge** for the mail-in service if you have already enrolled in the annual exam CME program, and we receive this exam during your current enrollment period. If you are not enrolled, please send \$33.00 per exam, or \$279 to cover all 10 exams (thus saving \$51 over the cost of 10 individual exam fees).

### Facsimile Grading

To receive your CME certificate, complete all information and fax 24 hours a day to 1631-532-1964. Your CME certificate will be dated and mailed within 48 hours. This service is available for \$2.95 per exam if you are currently enrolled in the annual 10-exam CME program (and this exam falls within your enrollment period), and can be charged to your Visa, MasterCard, or American Express.

If you are *not* enrolled in the annual 10-exam CME program, the fee is \$33 per exam.

### Phone-In Grading

You may also complete your exam by using the toll-free service. Call 516-521-4474 from 10 a.m. to 5 p.m. EST, Monday through Friday. Your CME certificate will be dated the same day you call and mailed within 48 hours. There is a \$2.95 charge for this service if you are currently enrolled in the annual 10-exam CME program (and this exam falls within your enrollment period), and this fee can be charged to your Visa, Mastercard, American Express, or Discover. If you are not currently enrolled, the fee is \$33 per exam. When you call, please have ready:

1. Program number (Month and Year)
2. The answers to the test
3. Credit card information

In the event you require additional CME information, please contact PMS, Inc., at **1-718-897-9700.**

## ENROLLMENT FORM & ANSWER SHEET

*Please print clearly...Certificate will be issued from information below.*

Name \_\_\_\_\_ Email Address \_\_\_\_\_

Please Print:      FIRST                      MI                      LAST

Address \_\_\_\_\_

City \_\_\_\_\_ State \_\_\_\_\_ Zip \_\_\_\_\_

Charge to:  Visa     MasterCard     American Express

Card # \_\_\_\_\_ Exp. Date \_\_\_\_\_ Zip for credit card \_\_\_\_\_

**Note: Credit card is the only method of payment. Checks are no longer accepted.**

Signature \_\_\_\_\_ Email Address \_\_\_\_\_ Daytime Phone \_\_\_\_\_

State License(s) \_\_\_\_\_ Is this a new address? Yes \_\_\_\_\_ No \_\_\_\_\_

**Check one:**  I am currently enrolled. (If faxing or phoning in your answer form please note that \$2.95 will be charged to your credit card.)

I am not enrolled. Enclosed is my credit card information. Please charge my credit card \$33.00 for each exam submitted. (plus \$2.95 for each exam if submitting by fax or phone).

I am not enrolled and I wish to enroll for 10 courses at \$279.00 (thus saving me \$51 over the cost of 10 individual exam fees). I understand there will be an additional fee of \$2.95 for any exam I wish to submit via fax or phone.

*Over, please*

**EXAM #8/23**  
**Radiographic Fundamentals Review**  
**(Armstrong)**

**Circle:**

- |            |             |
|------------|-------------|
| 1. A B C D | 6. A B C D  |
| 2. A B C D | 7. A B C D  |
| 3. A B C D | 8. A B C D  |
| 4. A B C D | 9. A B C D  |
| 5. A B C D | 10. A B C D |

**Medical Education Lesson Evaluation**

Strongly agree [5]	Agree [4]	Neutral [3]	Disagree [2]	Strongly disagree [1]
--------------------------	--------------	----------------	-----------------	-----------------------------

- 1) This CME lesson was helpful to my practice \_\_\_\_
- 2) The educational objectives were accomplished \_\_\_\_
- 3) I will apply the knowledge I learned from this lesson \_\_\_\_
- 4) I will make changes in my practice behavior based on this lesson \_\_\_\_
- 5) This lesson presented quality information with adequate current references \_\_\_\_
- 6) What overall grade would you assign this lesson?  
A B C D
- 7) This activity was balanced and free of commercial bias.  
Yes \_\_\_\_ No \_\_\_\_
- 8) What overall grade would you assign to the overall management of this activity?  
A B C D

How long did it take you to complete this lesson?  
\_\_\_\_ hour \_\_\_\_ minutes

What topics would you like to see in future CME lessons?  
Please list :

---

---

---

---

---