



Management of Wounds in the Trauma Patient

Recommended management varies based on the etiology of the wound.

BY ELLIANNE M. NASSER, DPM

Objectives

- Understand basic principles of wound management in the trauma patient.
- Demonstrate knowledge of treating lacerations, burns, bite wounds, puncture wounds, open fractures, crush injuries, and degloving injuries.
- Recognize indications for hyperbaric oxygen therapy in the trauma patient.

Welcome to Podiatry Management's CME Instructional program. Podiatry Management Magazine is approved by the Council on Podiatric Medical Education as a provider of continuing education in podiatric medicine. Podiatry Management Magazine has approved this activity for a maximum of 1.5 continuing education contact hours. This CME activity is free from commercial bias and is under the overall management of Podiatry Management Magazine.

You may enroll: 1) on a per issue basis (at \$33.00 per topic) or 2) per year, for the special rate of \$279 (you save \$51). You may submit the answer sheet, along with the other information requested, via mail, fax, or phone. You can also take this and other exams on the Internet at www.podiatrym.com/cme.

If you correctly answer seventy (70%) of the questions correctly, you will receive a certificate attesting to your earned credits. You will also receive a record of any incorrectly answered questions. If you score less than 70%, you can retake the test at no additional cost. A list of states currently honoring CPME approved credits is listed. Other than those entities currently accepting CPME-approved credit, Podiatry Management cannot guarantee that these CME credits will be acceptable by any state licensing agency, hospital, managed care organization or other entity. PM will, however, use its best efforts to ensure the widest acceptance of this program possible.

This instructional CME program is designed to supplement, NOT replace, existing CME seminars. The goal of this program is to advance the knowledge of practicing podiatrists. We will endeavor to publish high quality manuscripts by noted authors and researchers. If you have any questions or comments about this program, you can write or call us at: **Program Management Services, P.O. Box 490, East Islip, NY 11730, (718) 897-9700 or e-mail us at bblock@podiatrym.com.**

Following this article, an answer sheet and full set of instructions are provided.—Editor

Treatment of chronic wounds is common practice for the foot and ankle specialist. The typical chronic wound care patient is over the age of 50, neuropathic, with multiple co-morbidities. This creates many obstacles to wound healing given the impaired host. Wounds that occur in the trauma setting are discussed much less frequently. Ranging from minor to severe, traumatic wounds require prompt attention and meticulous

Traumatic wounds require prompt attention and meticulous wound care and assessment to assure a favorable outcome.

wound care and assessment to assure a favorable outcome. Although the traumatic wound care patient is typically younger and with minor or fewer co-morbidities, this patient

poses new challenges to wound care as s(he) is typically sensate.

Emergency Departments in the United States treat 12.2 million patients per year for emergency wound care.

It is the most frequently performed procedure second to IV insertion.¹ Given how common these visits are, it is not surprising that wound care comprises 5-20% of all emergency medicine malpractice claims and 3-11% of dollars paid out.² Some of the most common reasons for litigation are failure to diagnose foreign bodies, wound infections, and failure to detect underlying injuries.² Unfortunately, new patients frequently present for follow-up from an emergency department visit, only to discover a missed tendon injury or foreign body. These injuries are more difficult to treat as time passes, and patient outcomes worsen.

Basic Principles

As with all wound care, the practitioner must check for adequate perfusion. Vascular work-up should be performed to assess for chronic arterial or venous insufficiency, as well as acute compromise. Host factors must

be addressed, including smoking status, nutrition, and co-morbidities. Off-loading may be important if the wound is on the plantar foot. Edema control will assist in expediting wound closure. Infection and nonviable tissue must be managed appropriately with antibiotics and debridement. The micro-environment of the wound remains important, and wound care must adapt to the micro-environment as the wound changes. Dry wounds will need added moisture, draining wounds will need absorptive dressings to dry the wound. Pain is a particular concern for wounds in this patient population as patients are typically sensate. Aggressive debridement may need to be performed in the operating room, and office debridements and even dressing changes may require pre-medicating patients, as well as local nerve blocks and topical lidocaine.

Wounds in the emergency setting require thorough irrigation. Baseline x-rays should be performed to rule

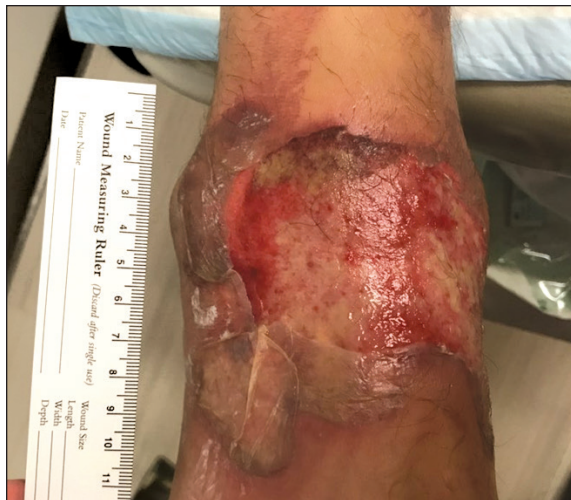

Figure 2: Burn wound to anterior ankle after spilling hot oil. Wound healed in 5 weeks with local debridement, Silver Sulfadiazine, and compression.

surgical treatment depends on the severity and presentation of the wound.

Lacerations

The average laceration presenting to the emergency department is 1-3 cm, with 13% considered “significantly contaminated.”¹ 3.5 -6.3% of lacerations will develop an infection, which is the most common complication.¹ Thorough irrigation is the most important step for reducing infection. The treating provider should have a high index of suspicion for an underlying tendon injury with lacerations. MRI or Ultrasound are the imaging studies of choice to rule out soft tissue injury. Once underlying soft tissue injury is ruled out, the wound can be closed primarily pending severity and contamination.

Dry wounds will need added moisture, draining wounds will need absorptive dressings to dry the wound.

be addressed, including smoking status, nutrition, and co-morbidities. Off-loading may be important if the wound is on the plantar foot. Edema control will assist in expediting wound closure. Infection and nonviable tissue must be managed appropriately with antibiotics and debride-

ment. The micro-environment of the wound remains important, and wound care must adapt to the micro-environment as the wound changes. Dry wounds will need added moisture, draining wounds will need absorptive dressings to dry the wound. Pain is a particular concern for wounds in this patient population as patients are typically sensate. Aggressive debridement may need to be performed in the operating room, and office debridements and even dressing changes may require pre-medicating patients, as well as local nerve blocks and topical lidocaine.

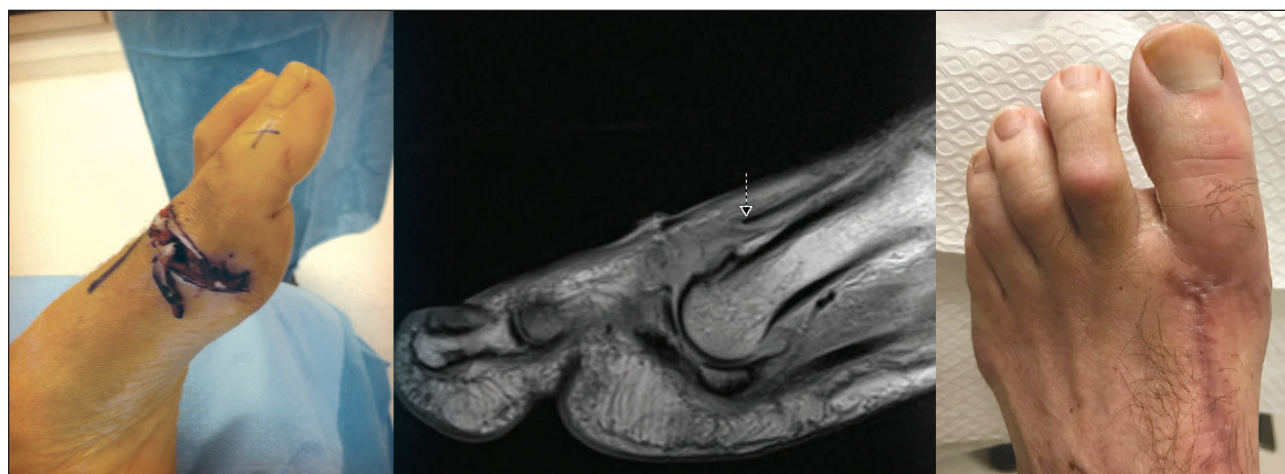


Figure 1: Laceration caused by chain saw injury with associated extensor hallucis longus tendon rupture.

Figure 1 demonstrates a 61-year-old healthy male who suffered a chainsaw injury. The patient presented to the Emergency Department with a first metatarsophalangeal joint laceration and associated extensor hallucis longus tendon injury. Tetanus status was assessed, antibiotics administered, and irrigation performed in the emergency department. MRI revealed a greater than 2 cm gap at the extensor hallucis longus tendon. Surgical repair was required for irriga-

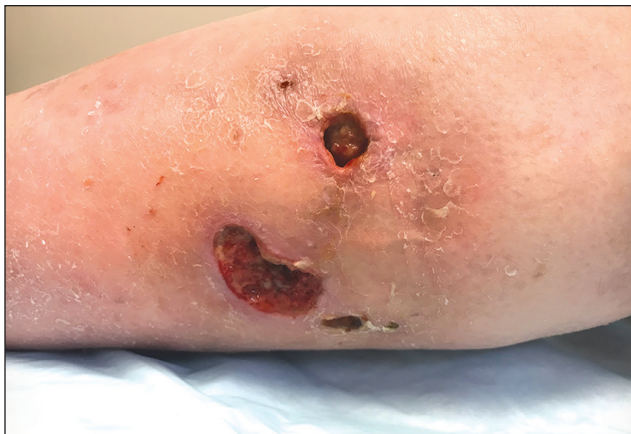

Figure 3: Wound to lateral leg following cat bite. Wound healed in 8 weeks with debridement, local wound care, and compression.

Bite Wounds

An estimated two billion bite wounds occur each year in the United States. Surprisingly, 3.6-23% of these are human bite wounds.¹ Irrigation and debridement is key to wound management and closure. Deep puncture wounds should be opened for thorough irrigation. Dilute povidone iodine solution can be used for irrigation. The antibiotic of choice for dog and cat bites is amoxicillin/clavulanate.¹

An 83-year-old patient in Figure 3 presented four weeks following a cat bite, after two courses of antibiotics and local wound care by her primary care physician. The wound was complicated by concomitant venous insufficiency. Following a vascular workup, compression therapy was initiated. The patient healed in eight weeks with debridements every other week. Topical lidocaine was applied prior to debridements. Wound care was initiated with saline wet to dry, as wounds initially connected. Wound care was switched to a freeze-dried collagen matrix with oxidized regenerated cellulose once tunneling filled in.

Puncture Wounds

Puncture wounds are common on the plantar surface of the foot and are caused typically by a sharp object

Appropriate management of burns includes debridement of necrotic tissue.

tion, debridement, tendon repair, and repair of a capsular defect with an autograft. The patient healed the laceration within one month of surgery with no complication. He regained full dorsiflexory strength at his metatarsophalangeal joint with some residual stiffness to the joint.

Burns

Over a million patients sustain burn injuries each year in the United States, with approximately 4.5% of these patients hospitalized.³ The extent of the burn is measured by the total body surface area of second and third-degree burns. If the second degree burn total is less than 15% of the total body surface area, the burn can be managed as an outpatient.³ Appropriate management starts with debridement of necrotic tissue. Intact blisters are controversial; if they are large and friable it is recommended to remove them, if they are small they can be left intact to provide protection over the underlying injury. Pain control is difficult in burn patients, particularly with debridement. Topical lidocaine is commonly used prior to

debridements, and often oral analgesics or even surgical debridement is necessary. Silver sulfadiazine is a common treatment, combined with a non-adherent dressing. Tetanus status should be addressed.³

Figure 2 demonstrates the initial presentation of a 61-year-old healthy male who suffered a burn to his anterior ankle after spilling scalding hot oil while working in a restaurant. The wound healed in five weeks with local wound care consisting of debridement, silver sulfadiazine, and compression. Topical Lidocaine was used prior to debridements.

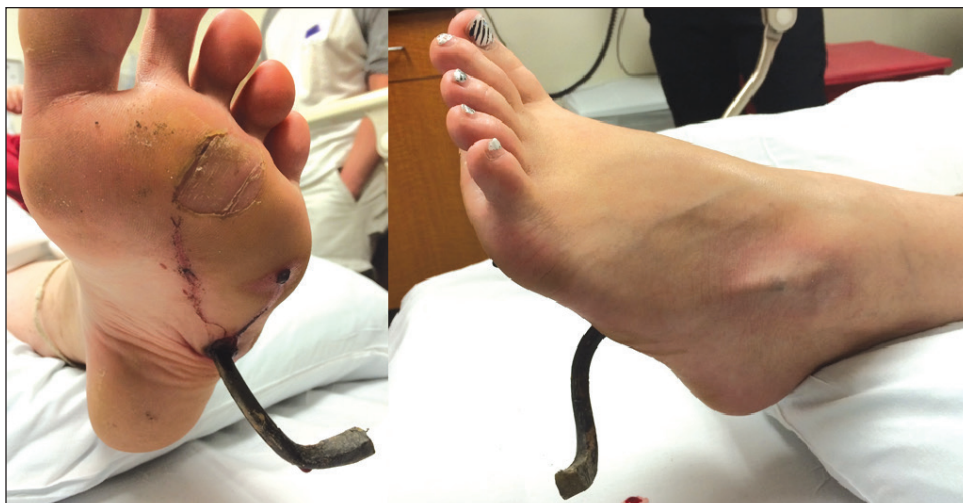

Figure 4: Puncture wound after stepping on a gardening tool while barefoot. Wound healed uneventfully following surgical removal of foreign body and washout.

penetrating the skin. Tetanus status must be addressed upon presentation, and antibiotics initiated. X-rays should be ordered to assess for a bony injury and/or foreign body. MRI or Ultrasound should be ordered if soft tissue injury or a foreign body is suspected.

Figure 4 demonstrates a puncture wound in a 21-year-old female after stepping on a gardening tool bare-foot. Her father cut the remainder of the tool off prior to presentation. A tetanus booster and antibiotics were administered in the emergency department. The patient was taken for emergent removal of the foreign body in the operating room. An ancillary incision was created to the dorso-lateral foot at the area of skin tenting. Grass and debris were expressed from this ancillary incision, and the area was flushed using gravity la-

ronment through a break in the skin. Open fractures of the tibia are the most common open long bone fracture, occurring in 3.4 per 100,000 people annually, primarily from high energy trauma.^{4,5} Since its description in 1976, the Gustilo Anderson Classification has been the most widely used classification for open fracture management. The rate of infection correlates with the grade of fracture, with 0-2%

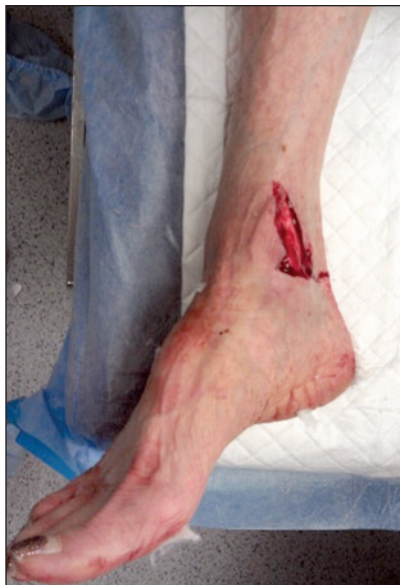

Figure 5: Open fracture following fall on the ice. Wound healed uneventfully following surgical washout and delayed primary closure.

systematic review looking at 3,539 open fractures and demonstrated no significant difference in the infection rate between open fractures debrided early or late according to any of the time thresholds used in the studies included.⁷

Recent studies have looked at the duration of antibiotic prophylaxis in adults with open lower extremity fractures.⁸ Results are unclear with no consensus. Only one random-

ized, double-blind, prospective study looked at the duration of antibiotic prophylaxis administration in open tibial fractures, and found that a short course of antibiotics is just as effective as a long course.⁹

Figure 5 demonstrates a 6 cm opening in a 65-year-old female who slipped on the ice and suffered an open trimalleolar ankle fracture. The patient had a history of rheumatoid arthritis and was taking methotrexate, and using tobacco. Antibiotics were administered in the emergency department and tetanus status was assessed.

Secondary to the instability of the fracture and contamination of the open wound, the patient was taken within six hours of presentation for application of a delta frame and washout of the opening with gravity lavage. Definitive fixation and closure was performed at a later date, and healing of the opening occurred without incident.

The antibiotic of choice for dog and cat bites is amoxicillin/clavulanate.

vage. Intra-operative fluoroscopy was used to assure that no residual foreign body was present after removal. Patient healed uneventfully within one month of surgery.

Open Fractures

Open fractures are fractures that communicate with the outside envi-

ronment through a break in the skin. In Grade I, 2-7% in Grade II, 7% in Grade IIIA, 10-50% in Grade IIIB, and 35-50% in Grade IIIC.⁶

Historically, emergent surgical debridement of open fractures was recommended within six hours of the injury; however, recent literature has challenged this recommendation. Schenker, et al. performed a

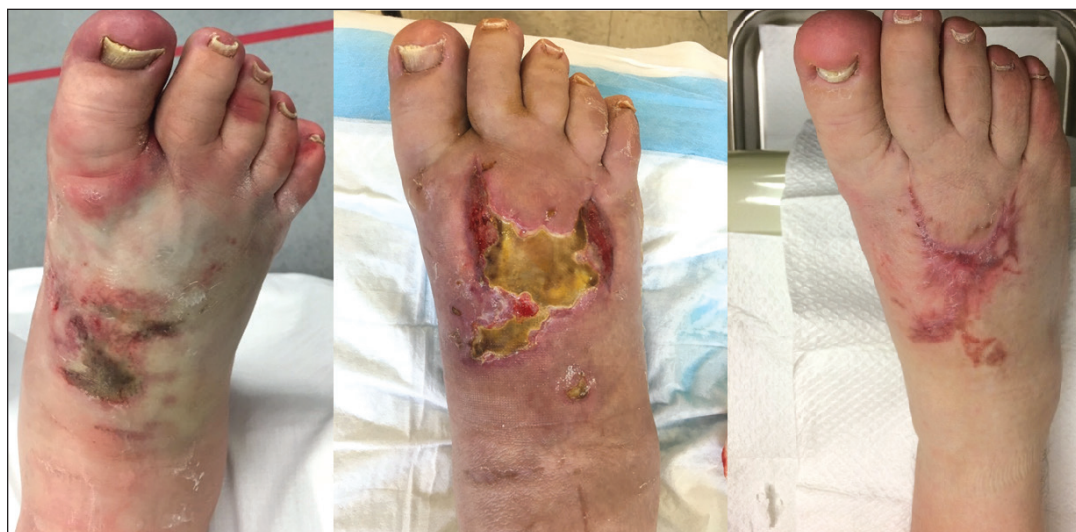

Figure 6: Crush injury and compartment syndrome after patient's foot got stuck under road milling machine. Wound healed at 4 months following emergent fasciotomy, debridements, and skin substitute application.

Crush Injury

Crush injuries occur when a body part is forcefully compressed between two hard surfaces, where the compression blocks the flow of blood and oxygen leading to isch-

Degloving Injury

Degloving injuries to the lower extremity are devastating, complex, limb salvage injuries. These injuries are characterized by separation of the subcutaneous tissue and at times

administered in the Emergency Department. The patient refused transmetatarsal amputation at initial presentation. She was treated with stabilization of concomitant fractures and dislocations, debridement, and application of wound VAC. She underwent multiple washouts using gravity lavage. Secondary to contamination of the site and severe pain with attempt at dressing change or manipulation of the surgical site, all wound VAC changes were performed in the operating room for the first week. She ultimately went on to a transmetatarsal amputation, followed by a combination of partial and full thickness skin grafts with plastic surgery.

In the Gustilo Anderson Classification, Grade IIIB injuries have a 10-50% infection rate.

emia.¹⁰ These injuries are often associated with multiple fractures and severe soft tissue damage. Prolonged crush injuries have a higher incidence of neurovascular compromise. Skin necrosis is a frequent complication, particularly with prolonged exposure to the crush. Compartment syndrome is a serious concern, and

bony architecture from its surrounding anatomy. A multi-disciplinary approach is vital for these cases, with plastic surgery playing a major role in limb salvage and soft tissue deficit reconstruction. Unfortunately, many of these cases result in partial foot amputation or even more proximal amputation. Degloving injuries re-

Hyperbaric Oxygen Therapy

Hyperbaric oxygen therapy

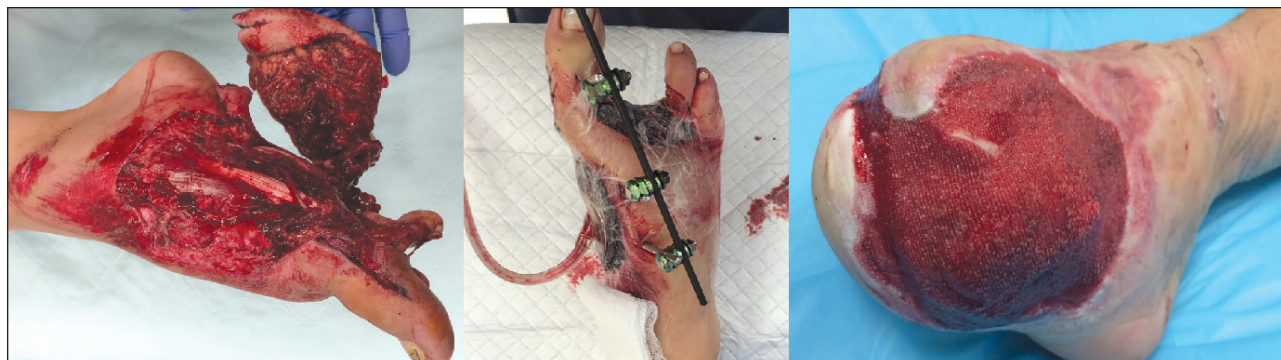


Figure 7: Degloving injury after patient was struck by a vehicle. Following emergent reduction, washout, and partial amputation, patient underwent serial washouts prior to transmetatarsal amputation.

patients must be monitored closely for possible fasciotomy.

Figure 6 demonstrates a 50-year-old obese male who had his foot stuck under a road milling machine for 45 minutes. The patient presented with signs of acute compartment syndrome, with early skin necrosis to the dorsal foot. A tetanus booster and antibiotics were administered in the emergency department. The patient was treated with emergent fasciotomy, repeat washout and debridement, and debridement with skin substitute at one month following injury. Topical lidocaine was applied prior to debridements in the wound care center, with more aggressive debridements performed in the operating room. The patient healed at four months following initial injury.

Treatment of degloving injuries may include amputation.

quire multiple washouts using gravity lavage. High pressure lavage is not indicated, and can cause further trauma to the already compromised soft tissue. Negative pressure wound therapy is beneficial in providing a barrier between the exposed muscle/tendon/bone and the environment, as well as promoting granulation tissue which can prepare the wound for a future flap or graft.

Figure 7 outlines the progression of a 33-year-old female with a history of IV drug abuse who presented after being struck by a vehicle. A tetanus booster and antibiotics were

(HBOT) has been widely used in lower extremity wound care. A patient's whole body is physically exposed to 100% oxygen and atmospheric pressure that is greater than 1 atmosphere absolute (ATA).¹¹ HBOT provides multiple benefits for wound healing including angiogenesis, fibroblast growth, collagen production, improved osteoclast function, inhibition of α -toxin production in clostridial myonecrosis, improvement in leukocyte killing, decrease in neutrophil adherence to capillary walls, and edema reduction.¹²⁻¹⁷ An absolute contraindication to HBOT is an untreated

ed pneumothorax, which may present in the trauma patient.

Relative contra-indications include pregnancy, emphysema, pneumonia, bronchitis, cardiac disease, recent thoracic surgery, and hyperthermia.¹²

HBOT has been recommended in lower extremity trauma patients including those with crush injuries, open fractures, compartment syndrome, and thermal burns. These injuries share common pathophysiology of a triad of tissue ischemia, hypoxia, and edema, a gradient of tissue injury, and a capacity for the injury to continue and worsen.¹³ All of these injuries include some type of initial “crush” causing a primary zone of destruction which is an area of injured tissue that will be nonviable regardless of intervention. The secondary injury includes a zone of variably injured tissue involving ischemia, hypoxia, and edema. HBOT is targeted at minimizing and preventing secondary injury resulting from ischemia, hypoxia, and edema.¹³ A third zone of non-injured tissue may become damaged in a self-perpetuating injury, which is also prevented or improved with HBOT.

HBOT minimizes secondary injury by four main mechanisms.^{14,15} Enhanced oxygen delivery can increase the effective diffusion volume up to sixteen-fold. Edema reduction occurs through vasoconstriction, with the high oxygen content of the blood more than compensating for any reduction in blood flow. HBOT disturbs neutrophil adherence to the post-capillary venule leading to re-perfusion and prevention of release of toxic oxygen free radicals. Host factors are improved as leukocyte function is enhanced, which can help to control infection and repair injured tissues.^{14,15}

If indicated, HBOT is initiated as soon as the patient is stabilized and any major vascular injury is addressed. Treatment starts at 2.4 ATA for 90 minutes with 100% oxygen. Ten to twelve daily treatments may be required, which would occur alongside debridement, fracture and wound management, and antibiotics.¹⁴

Although the benefits of HBOT in the trauma patient have been well documented, guidelines for clinical

application are limited. Current literature includes case reports and small retrospective series. Garcia-Covarrubias, et al. performed a systematic review including nine papers and 150 patients looking at the use of HBOT in management of crush injury and traumatic ischemia. Most of the studies were retrospective case series with only one prospective controlled randomized trial. The authors determined that eight of the nine studies showed a beneficial effect from HBOT with only one major complication, and concluded that HBOT could be beneficial if administered early.¹⁶

In a retrospective controlled cohort study, Yamada, et al. reviewed patients with crush injuries and open fractures with severities greater than or equal to Gustilo Class IIA. 16 patients received HBOT, and 13 patients were in the control group. The incidence of infection was significantly lower in the HBO group, although durations of the Intensive Care Unit and hospital stays were similar.¹⁷

A prospective, randomized, blinded, multi-center study is currently underway looking at HBOT in acute open tibia fractures of Gustilo Grade III. Primary outcome measures will look at the incidence of acute complications of the open fracture at 14 days. Long-term follow-up will continue for two years post-injury.¹⁸

Conclusion

The traumatic wound care patient is complex, typically with associated injuries and contamination of the wound. Patients are typically sensate, which poses a challenge in treatment, debridement, and dressing changes. Recommended management varies based on the etiology of the wound. A thorough exam and assessment for associated bone and soft tissue injury helps to dictate an appropriate treatment plan. Tetanus status should be assessed, and

prophylactic antibiotics considered. Basic wound care principles are followed with particular attention to pain control, associated injuries, and infection prevention. **PM**

References

¹ Trott A. Wounds and Lacerations: Emergency Care and Closure. Fourth Edition. Philadelphia, PA: Saunders; 2012.

² Pfaff JA, Moore GP. Reducing Risk in Emergency Department Wound Management. *Emerg Med Clin N Am* 25 (189-201), 2007.

³ Gomez R, Cancio CLC. Management of Burn Wounds in the Emergency Department. *Emerg Med Clin N Am* 25 (135-146), 2007.

Hyperbaric oxygen therapy is indicated in patients with crush injuries.

⁴ Browner BD, Jupiter JB, Levine AM, Trafton PG, Krettek C, editors. Skeletal trauma: basic science, management, and reconstruction. 4th ed. Philadelphia, PA: W.B. Saunders Company; 2008.

⁵ DeLee JC, Stiehl JB. Open tibia fracture with compartment syndrome. *Clin Orthop Relat Res.* (160) 175-84, 1981.

⁶ Gustilo RB, Anderson JT. Prevention of infection in the treatment of one thousand and twenty-five open fractures of long bones: retrospective and prospective analyses. *J Bone Joint Surg Am* 58: 453-458, 1976.

⁷ Schenker ML, Yannascoli S, Baldwin KD, Ahn J, Mehta S. Does Timing to Operative Debridement Affect Infectious Complications in Open Long-Bone Fractures? A Systematic Review. *J Bone Joint Surg* (94) 1057-64, 2012.

⁸ Isaac SM, Woods A, Danial IN, Mourkus H. Antibiotic prophylaxis in adults with open tibial fractures: what is the evidence for duration of administration: a systematic review. (55) 146-150, 2016.

⁹ Dellinger EP, Caplan ES, Weaver LD, Wertz MJ, Droppert BM, Hoyt N, Brumback, Burgess A, Poka A, Benirschke KSK. Duration of preventative antibiotic administration for open extremity fractures. *Arch Surg* 123: 333-339, 1988.

¹⁰ Boernert K, Ganot G, Ulrich MK, Iselin LD. Preserving the lower extremity after severe degloving injuries to meet the patient's demand in two cases (limb salvage after degloving injury). *Trauma Case Reports* 15: 8-15, 2018.

¹¹ Bryant R, Nix D. Acute and chronic

wounds: current management concepts. St. Louis, MOL Mosby, Elsevier; 2007.

¹² Dougherty JE. The role of hyperbaric oxygen therapy in crush injuries. Crit Care Nurse Q. 36(3) 299-309, 2013.

¹³ Buettner MF, Wolkenhauer D. Hyperbaric oxygen therapy in the treatment of open fractures and crush injuries. Emerg Med Clin N Am (25) 177-188, 2007.

¹⁴ Greensmith JE. Hyperbaric oxygen therapy in extremity trauma, J American Ac Othop Surgeons. 12(6) 376-384, 2004.

¹⁵ Strauss MB. Crush injury, compartment syndrome, and other acute traumatic peripheral ischemias. In Kindwall E, Whalen H, editors. Hyperbaric medicine practice. 2nd edition. Flagstaff AZ. Best Publishing Company p 760, 2002.

¹⁶ Garcia Covarrubias L, McSwait N, Can Meter K, Bell RM. Adjuvant hyperbaric oxygen therapy in the management of crush injury and traumatic ischemia: an evidence-based approach. The American Surgeon. 71(144-151), 2005.

¹⁷ Yamada N, Toyada I, Doi T et al. Hyperbaric oxygen therapy for crush injuries reduces risk of complications: research report. UHM 41(4): 283-289, 2-14.

research report. UHM 41(4): 283-289, 2-14.

¹⁸ Millar IL, McGinnes RA, Williamson O, Lind F, Jansson K, Hajek M, Smart D, Fernandes T, Miller R, Myles P, Cameron P. Hyperbaric oxygen in lower limb trauma (HOLLT); protocol for a randomized controlled trial. BMJ Open 2015.



Dr. Nasser is an Associate of Podiatry with Geisinger Health System. She is a Diplomate of the American Board of Podiatric Medicine, American Board of Foot and Ankle Surgery, and American Board of Wound Management. Dr. Nasser serves as the Assistant Program Director, Podiatric Medicine and Surgery Residency at Geisinger Community Medical Center.

CME EXAMINATION

1) Basic principles of wound care include all of the following except:

- A) Addressing host factors such as smoking status, nutrition, and co-morbidities.
- B) Ignoring signs of infection when they present at the area of the wound.
- C) Edema control
- D) Assessing the patient for adequate perfusion

2) Methods of providing pain control when performing debridement or dressing changes in the sensate patient include:

- A) Topical lidocaine
- B) Local Anesthesia injection
- C) Oral analgesics
- D) All of the above

3) Which of the following is NOT true about lacerations:

- A) You do not need to repair them.
- B) Thorough irrigation is the most important step for preventing infection.
- C) The average laceration presenting to the ED is 1-3cm.
- D) The treating provider should have a high index of suspicion for underlying soft tissue injury.

4) Appropriate management of burns includes:

- A) Debridement of necrotic tissue
- B) Deferring debridement secondary to pain
- C) Saline wet to dry
- D) Leaving the wound open to the air

5) The antibiotic of choice for dog and cat bites is:

- A) Bactrim
- B) Clindamycin
- C) Amoxicillin/clavulanate
- D) Ciprofloxacin

6) All of the following are true regarding management of puncture wounds except:

- A) Tetanus status must be addressed upon presentation.
- B) X-rays should be ordered to rule out bony injury or retained foreign body.
- C) Ultrasound or MRI may be necessary to rule out soft tissue injury.
- D) If present, the penetrating object should be left in the foot.

- 7) Which of the following is true regarding the rate of infection in the Gustilo Anderson Classification?
- A) Grade I injuries have a 10% infection rate.
 - B) Grade II injuries have a 10% infection rate.
 - C) Grade IIIA injuries have a 10% infection rate.
 - D) Grade IIIB injuries have a 10-50% infection rate.
- 8) All of the following are true regarding crush injuries except:
- A) Crush injuries occur when a body part is compressed between two hard surfaces.
 - B) Crush injuries often lead to ischemia.
 - C) Compartment syndrome is common in crush injuries.
 - D) Crush injuries are not painful.
- 9) Treatment of degloving injuries may include:
- A) Conservative care without surgical intervention
 - B) Amputation
 - C) High pressure lavage/washout
 - D) Discharge from the hospital after presentation in the emergency department
- 10) Hyperbaric oxygen therapy is indicated in patients with the following injury:
- A) Crush injury
 - B) Toe fracture after stubbing foot on bed stand
 - C) 2 cm laceration
 - D) Dog bite

The author(s) certify that they have NO affiliations with or involvement in any organization or entity with any financial interest (such as honoraria; educational grants; participation in speakers' bureaus; membership, employment, consultancies, stock ownership, or other equity interest), or non-financial interest (such as personal or professional relationships, affiliations, knowledge, or beliefs) in the subject matter or materials discussed in this manuscript.

PM's CME Program

Welcome to the innovative Continuing Education Program brought to you by *Podiatry Management Magazine*. Our journal has been approved as a sponsor of Continuing Medical Education by the Council on Podiatric Medical Education.

Now it's even easier and more convenient to enroll in PM's CE program!

You can now enroll at any time during the year and submit eligible exams at any time during your enrollment period.

CME articles and examination questions from past issues of *Podiatry Management* can be found on the Internet at <http://www.podiatrym.com/cme>. Each lesson is approved for 1.5 hours continuing education contact hours. Please read the testing, grading and payment instructions to decide which method of participation is best for you.

Please call (718) 897-9700 if you have any questions. A personal operator will be happy to assist you.

Each of the 10 lessons will count as 1.5 credits; thus a maximum of 15 CME credits may be earned during any 12-month period. You may select any 10 in a 24-month period.

The Podiatry Management Magazine CME program is approved by the Council on Podiatric Education in all states where credits in instructional media are accepted. This article is approved for 1.5 Continuing Education Contact Hours (or 0.15 CEU's) for each examination successfully completed.

PM's privacy policy can be found at <http://podiatrym.com/privacy.cfm>.

This CME is valid for CPME-approved credits for three (3) years from the date of publication.

EXAM #2/22

**Management of Wounds in the Trauma Patient
(Nasser)**

Circle:

1. A B C D

6. A B C D

2. A B C D

7. A B C D

3. A B C D

8. A B C D

4. A B C D

9. A B C D

5. A B C D

10. A B C D

Medical Education Lesson Evaluation

Strongly
agree
[5]

Agree
[4]

Neutral
[3]

Disagree
[2]

Strongly
disagree
[1]

1) This CME lesson was helpful to my practice ____

2) The educational objectives were accomplished ____

3) I will apply the knowledge I learned from this lesson ____

4) I will make changes in my practice behavior based on this lesson ____

5) This lesson presented quality information with adequate current references ____

6) What overall grade would you assign this lesson?

A B C D

7) This activity was balanced and free of commercial bias.

Yes ____ No ____

8) What overall grade would you assign to the overall management of this activity?

A B C D

How long did it take you to complete this lesson?

____ hour ____ minutes

What topics would you like to see in future CME lessons?

Please list :
