

# Principles and Practice of Podiatric Medicine

This important new book by Drs. Hetherington and Levy encompasses a wide range of topics.

**Editor's Note:** This is the third in an occasional series in which new Data Trace books are introduced to PM readers via selected excerpts. Data Trace Publishing Company has been a leading publisher in the podiatry field since 1989.

The following chapter has been excerpted:

## Chapter 45 Pes Cavus

### Pes Cavus

Pes cavus is a complex and often multisegmental deformity of the forefoot, midfoot, hindfoot, and ankle joint. It is generally defined as a foot with an abnormally high arch when

viewed from a lateral profile. There is no universally accepted radiographic definition of pes cavus. Pes cavus was first identified as a specific deformity by Little in 1853. Historically it has been referred to as hollow foot, claw-foot, bolt foot, pes arcuatus, talipes plantaris, griffe pied creux, Holfuss,

*Continued on page 66*

## Principles and Practice of Podiatric Medicine


**L**eonard A. Levy, DPM, MPH and Vincent J. Hetherington DPM, MS serve as the editors of this one-stop resource on current podiatric medical practice. Since 1999 Leonard A. Levy, DPM, MPH, has been Associate Dean for Education, Planning and Research at Nova Southeastern University College of Osteopathic Medicine. In 2009 he was the first podiatric physician in the world to be selected as a Fulbright Scholar serving at the Faculty of Medicine of Comenius University in Bratislava, Slovakia. Dr. Levy is Professor of Family Medicine/Public Health/Biomedical Informatics and since 9/11 has directed the Institute for Disaster and Emergency Preparedness at NSU-COM, one of seven in the nation selected for the National Education Strategy Team (NEST).

Vincent J. Hetherington DPM, MS is currently the Vice President and Dean of Academic Affairs for the Department of Surgery at Ohio College of Podiatric Medicine as well as an Adjunct Assistant Professor in the Department of Biomedical Engineering at Case Western Reserve University. Dr. Hetherington re-

ceived his Doctor of Podiatric Medicine at the College of Podiatric Medicine in Philadelphia in 1977 and later received his masters from Pennsylvania College of Podiatric Medicine in 1981.

Together both editors bring you *Principles and Practice of Podiatric Medicine*. The text's wide reaching scope encompasses major topics like foot and ankle disorders and injuries, surgical procedures, and rehabilitation, as well as insights into behavioral medicine, alternative therapies, and the role podiatry plays in the fight against epidemics and disease.

For more information about *Principles and Practice of Podiatric Medicine* or to order your copy today please call 1-800-342-0454 or visit [DataTrace.com](http://DataTrace.com). •



Dr. Levy



Dr. Hetherington

and nondeforming clubfoot. Clinical presentation and symptomology are variable depending on the cause.

Cavus foot varies in severity from mild to severe, sometimes with disabling lower extremity effects. It may be an isolated entity manifesting as anterior plantarflexed first ray, medial column cavus (idiopathic), global involving the entire forefoot and midfoot, or pre-

---

---

**The cause of pes cavus  
is a combination of neuromuscular  
imbalance and biomechanical dysplasia  
of the joints of the foot and ankle.**

---

---

dominantly posterior and combined. The entity may also be static due to “fixed” nerve injury or more likely slowly progressive with neuromuscular origin and dynamic imbalance. Multiplanar involvement is common rather than single plane deformity; however the sagittal plane is usually the most dominant component clinically. The degree of “fixation” or rigidity defines another important

.....

consideration since the deformity can be flexible, semi-flexible or entirely rigid. The mechanisms of foot, ankle, and leg mechanical compensation differ based on the severity and classification.

The complex presentation and compensation patterns of this deformity make classification difficult and confusing. The actual clinical presentation of this deformity often depends on the mechanism of biomechanical compensation, which can occur through the first ray segment or the entire Lisfranc level with dorsiflexion, the oblique and longitudinal axis of the midtarsal joint with pronation, the subtalar joint with inversion, and the ankle joint with external rotation and talar dorsiflexion.

One must search for the “origin” of this deformity like a detective since the cause can be elusive and multifactorial. Because of the significant correlation between neuromotor dysfunction at every level, it is imperative that a thorough history and physical examination of the patient and, at times, the family be conducted. A thorough examination may include evaluation of motor and sensorymotor function, reflex arcs, coordination electromyographic and nerve-conduction studies, clinical gait evaluation, foot-print recording, and actual deformity assessment identifying a classification type.

**Etiology**

Pes cavus is a reflection of abnormal biomechanics. The deformity is a continuum that can begin in the forefoot, midfoot, or hindfoot. Compensation must occur in order for gait mechanics to maintain function. This occurs through intrinsic movements in the foot, ankle and leg. Mechanical advantage of the various muscles about the peritalar and forefoot axes will result in positional imbalances of the forefoot, tarsus, and ankle joint and vice versa.

The cause of pes cavus is a combination of neuromuscular imbalance and biomechanical dysplasia of the joints of the foot and ankle. Mild forms of a high arched foot can fall within normal limits of a functionally normal foot. There is no real definition as to when “normal” is exceeded, but most clinicians recognize the break-off point when encountered. Radiographic standards are available for consideration regarding critical angular relationships of the foot and ankle which help define when normal is exceeded. These do not represent universally accepted standards, however. These standards, by and large, utilize lateral radiographic criteria.

Meary’s angle, formed by the longitudinal talar-first metatarsal angle. Hibbs’ angle, formed by the cal-

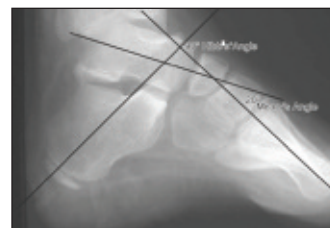


Figure 45-2: Meary’s first metatarsal-talar angle and Hibbs’ calcaneal inclination—first metatarsal angle.

caneal inclination angle and first metatarsal axis, form the two most common radiographic assessments (Fig. 45-2).

The development of pes cavus must be on the basis

*Continued on page 68*

of biomechanical imbalance. This situation arises from overt or subtle muscular imbalance. Taking this concept further makes it apparent that muscular imbalance can arise from structural imbalance first creating mechanical advantage for various muscles, or alternatively, from primary or secondary neuromotor disease setting up the scenario of dynamic motor imbalance. Neuromuscular disease can be acquired, con-

unusual spastic forms of pes cavus. Careful history and physical examination are required as part of the treatment process.

### **Pathomechanics and Classification**

#### **Anterior Cavus**

Selective anterior cavus manifests a dominant equinus of the forefoot relative to the hindfoot. It is expressed clinically and radiographically

develops early in most cavus feet, along with efforts to passively reduce the deformity in stance (Fig. 45-3).

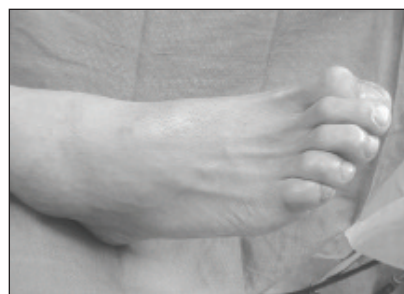

Figure 45-3: Digital clawing with metatarsal head prominence in forefoot cavus

## **Digital clawing with metatarsal head prominence often develops early in most cavus feet, along with efforts to passively reduce the deformity in stance**

Ankle dorsiflexion (talar dorsiflexion) must occur to some degree for compensation if global equinus forefoot rigidity is established, in order for gait to be functional. In the early stage, the deformity is passively reducible with the Kelikian push-up test and purely sagittal plane; however, later it becomes rigid and fixated (Fig. 45-4).

genital, genetic, or idiopathic in the neurologic system. Traumatic (post-calcaneal fracture), infectious, and spontaneous neurologic lesions such as spinal cord neoplasms can also initiate the deforming process. The exact distribution of the neuromuscular paresis or paralysis pattern will determine the type and severity of pes cavus encountered.

The spinocerebellar variants such as Friedreichs ataxia and Roussy-Levy, as well as the hereditary neuropathies such as Charcot-Marie-Tooth disease, all produce a similar pattern of progressive pes cavovarus and require special surgical considerations, usually involving tendon transfer and skeletal surgery for lasting correction and rebalance. Congenital lesions of the neuraxis and spinal dysplasias also typically produce a similar pattern progressive deformity.

The classification type and severity of the pes cavus will vary with the extent of neuromuscular involvement and genetic penetrance in the case of the hereditary neuropathies. Common to this grouping is progressive high arch architecture, clawing of the toes, prominence of the metatarsal heads, and developmental hindfoot varus deformity that becomes fixated usually at or prior to adolescence. Stroke or brain damage can result in

from the level of Chopart and Lisfranc joints forward. Paresis of tibialis anterior and/or the intrinsic musculature is often involved, forcing extensor substitution and digital buckling. The hindfoot is essentially normal in appearance and orientation. The characterization is made on a lateral radiograph and expressed clinically when viewed from the medial or lateral profile with the characteristic midfoot lump—this site also defines the apex of the deformity. There is no frontal plane hindfoot varus compensation in this cavus variant unless

the first metatarsal manifests rigid depression. Subsequent contracture of plantar intrinsic musculature and ligaments fixate the deformity, making correction or non-surgical accommodation more difficult and forcing biomechanical compensation to occur in the podiatric apparatus. Digital clawing with metatarsal head prominence often

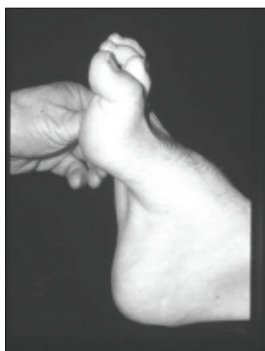

Figure 45-4: Kelikian push-up test to determine reducibility of cavus deformity.

This can set up a vicious cycle of deformity that subsequently draws the forefoot and hindfoot together in approximation, transforming the deformity into a combined anterior and posterior cavus. Usually this type of cavus remains local to the forefoot, but it can occasionally compensate with hindfoot approximation to gain heel contact in gait. More commonly, however, excessive talar dorsiflexion occurs at the

ankle for compensation. It is important to understand that both anterior and posterior cavus types always co-

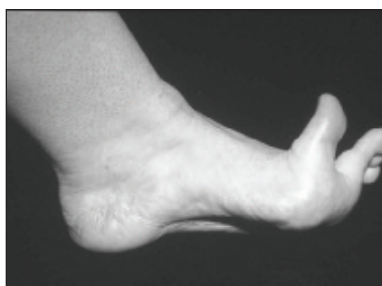

Figure 45-5: Windlass Mechanism of Hicks demonstrating tension banding of the plantar fascia with digital dorsiflexion

exist to some degree if the deformity is partially fixated, depending on the segmental radiographic and clinical dominance. The myofascial plantar aponeurosis mediates and also maintains the deformity through the Hicks windlass

*Continued on page 70*

and tension band mechanism (Fig. 45-5).

This concept further induces more rigidity into the deformity, making reduction passively or surgically more difficult. The other major ligaments of the tarsus, in particular the long and short plantar ligaments, also undergo

---

---

**True isolated posterior cavus  
in reality does not exist  
since this would represent a paralytic  
talipes calcaneus deformity instead.**

---

---

eventual contracture to help maintain the deformity. Anterior or forefoot equinus cavus is a separate and distinct deformity which can be partial or global involving only the first or all five metatarsals. The deformity occurs through Lisfranc or Chopart level and is characterized as a sagittal plane deformity. The clinician should identify the segment at which the deformity predominates—this is known as the apex and is determined in the sagittal plan. Clinically, one can usually visualize this phenomenon

.....

with a characteristic bump at the midfoot level over Lisfranc or Chopart's joint.

### **Posterior Pes Cavus**

Posterior cavus foot deformity is caused by partial paralysis or paresis of some of the calf musculature—in particular the gastrosoleus complex. The process may be genetic, congenital, or acquired. It develops when the secondary flexors and intrinsics compensate and draw the forefoot against the dorsiflexed hindfoot. The dominant component of this deformity is in the hindfoot with a dorsiflexed subtalar joint unit as viewed in the sagittal plane (Fig 45-6).

This fact differentiates this form of cavus from the anterior dominant variety. In most situations, this results from a specific neuromuscular imbalance in which the triceps surae is partially paralyzed or weakened, with the remaining dorsiflexors and forefoot plantar flexors varying in strength. The paralysis or paresis can have many causes. Poliomyelitis remains the most common cause, along with neuropathic processes that select out the gastrosoleus complex. Total tendo-Achilles injuries, lacerations, and paralyzes result in a progressive talipes calcaneus deformity, which is a separate and isolated deformity not encompassed in a posterior cavus deformity. The loss of normal strength of the triceps surae allows the gradual development of a vertical calcaneus, which in the adult results in a "pistol grip" deformity (Fig 45-7).

This shortens the lever arm upon which the triceps surae acts, thus creating a vicious cycle. The remaining secondary flexors are weaker calf muscles and result in diminished torque on the calcaneal tuber and apophysis with diminished growth. This scenario, when applied to a growing calcaneus, will lead to a shorter lever arm and weaker push-off.

The verticality of the calcaneus in conjunction with compensation by the intrinsics results in secondary auxiliary flexor compensation that draws the forefoot against the dorsiflexed hindfoot, producing calcanocavus, which then transforms into a combined cavus. Attempted compensation in a posterior cavus occurs through plantarflexion at the ankle in order to achieve forefoot surface contact in gait. Therefore, true isolated posterior cavus in reality does not exist since this would represent a paralytic talipes calcaneus deformity instead. **PM**

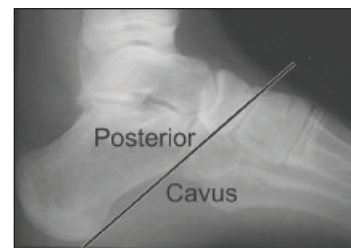


Figure 45-6: Posterior hindfoot cavus with sagittal plane subtalar joint deformity.

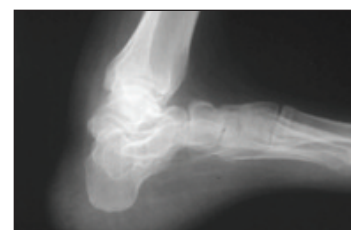

Figure 45-7: Calcaneal "pistol grip" posterior deformity with paralysis of the triceps surae.