



BY JARROD SHAPIRO, DPM

MRI Contrast: A Public Service Announcement

Warning: Don't give gadolinium to patients with renal disease.

Practice Perfect is a continuing every-issue column in which Dr. Shapiro offers his unique personal perspective on the ins and outs of running a podiatric practice.

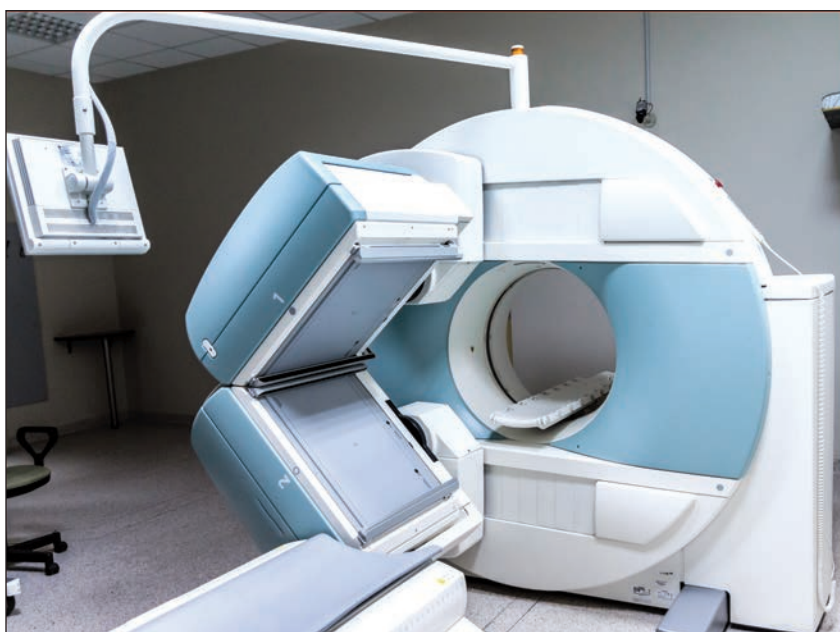In the ever-changing world of medicine, it's important for all healthcare providers to remain cognizant of changes that affect our patients' health. Many of us order magnetic resonance imaging (MRI) for various disorders affecting the body, and MRI has been a favorite modality for many of us due to its relative safety compared with radiography and computed tomography. Due to the lack of ionizing radiation and ability to obtain images with excellent clarity and anatomical detail, MRI has been the go-to modality for many physicians. Until recently.

Over the last few years, we have been introduced to complications that may result from the use of contrast materials. Before the mid-1990s, no one had heard of nephrogenic systemic fibrosis, and now come new findings about other issues regarding contrast materials for MRI.

To help stay informed, here is a public service announcement regarding gadolinium-based contrast agents for MRI. For the interested, there's also information about contrast agents for MRI and an important related clinical topic included below.

**Public Service Announcement—
Be Cautious with the Use of MRI
Contrast Agents**

A recent FDA safety alert has announced a new class warning regard-



ing the use of all gadolinium-based contrast agents, which can remain in the brain for months to years after administration. The FDA advises physicians to be aware of the characteristics of these agents and use contrast with caution in patients who are pregnant or might be pregnant, for repeated scans, those for children, and patients with inflammatory conditions or renal disease.¹ It's important to note that links between these contrast agents and other complications (besides nephrogenic systemic fibrosis) have not been definitely determined. More research will be necessary. *The FDA is recommending not avoiding the use of contrast agents for MRI when necessary, but to remain cautious when doing so.*

**Gadolinium-Based Contrast
Agents—A Primer²**

Gadolinium is a non-radioactive paramagnetic* lanthanide element. When in ionic form, it closely resembles Ca²⁺. As a result, it is cytotoxic and is therefore bound to a ligand. It is the ligand that is responsible for the multiple types of contrasts on the market today. These chelates (gadolinium bound to its ligand) can be ionic or non-ionic and linear or cyclical. The more strongly the gadolinium is bound, the less it interacts with tissues and the better its excretion. Macrocyclic contrast agents are the most strongly bound and stable. The three macrocyclic contrast agents are gadoteridol (ProHance[®]), gadobutrol (Gadavist[®]), and gadoterate meglumine (Dotarem[®]).

Continued on page 40

PRACTICE PERFECT

MRI (from page 39)

Most agents are excreted unchanged from the kidney with a half-life of 1.3 hours in healthy patients and 10 to 34 hours in those with renal disease.

Nephrogenic Systemic Fibrosis (NSF)

Nephrogenic systemic fibrosis (NSF) is a complication seen only in renal disease patients after the administration of gadolinium-based contrast agents. It is characterized primarily by thickening and hardening of the skin in the extremities and trunk, with dermal layer fibrosis. Patients undergoing peritoneal dialysis may be at higher risk than those undergoing hemodialysis, but all renal disease patients are considered at risk.

Podiatrists should be aware of the clinical appearance of this disorder due to its tendency to affect the ankles, lower legs, feet, and hands early in the disease process. It presents as symmetrical, bilateral, fibrotic, papules or nodules that may or may not be erythematous. This may be misdiagnosed as cellulitis (which is rarely bilaterally distributed). It may also present with a thick, indurated orange peel-like appearance that may mimic chronic venous disease changes. Late in the disease, hairlessness, atrophy,

and hyperpigmentation may occur, again mimicking venous disease. Other differentials include scleroderma, calciphylaxis, and cutaneous malignancy. Deep incisional or punch biopsy that extends into the muscle makes the diagnosis and should be performed.

Treatment of NSF is aimed at improving renal function, which has

function before ordering MRI with contrast, and when in doubt, communicate with the patient's primary care doctor and nephrologist. Additionally, inform all patients on whom MRI with contrast is planned of the long-term deposition of gadolinium-based contrast agents in the brain with its uncertain long-term effects. **PM**

**For podiatrists, the message is clear:
Don't give gadolinium to patients with renal disease.**

been shown to somewhat improve the symptoms of this disorder. Other treatments have yet to prove efficacy. Otherwise, prevention of NSF is the current primary approach by avoiding gadolinium-based contrast agents in patients with renal disease. This approach has significantly decreased the NSF cases in recent years. Alternatives include giving iodinated contrast and, when deemed absolutely necessary in renal disease patients, giving gadolinium, performing dialysis immediately afterward, and using macrocyclic gadolinium chelated products.

For podiatrists, the message is clear: *Don't give gadolinium to patients with renal disease.* Check renal

*For the physics geeks among us, paramagnetism refers to the fact that when two electrons have the same spin, their magnetic fields add together.

References

¹ FDA Alert. Gadolinium-based Contrast Agents (GBCAs): Drug Safety Communication—Retained in Body; New Class Warnings. 12/19/2017. Last accessed 1/17/2018.

² Miskulin D and Rudnick M. Nephrogenic systemic fibrosis/nephrogenic fibrosing dermatopathy in advanced renal failure. UpToDate*. Last accessed 1/8/2018.



Dr. Shapiro is editor of PRESENT Practice Perfect. He joined the faculty of Western University of Health Sciences, College of Podiatric Medicine, Pomona, CA in 2010.

PRESENT Podiatry

PRESENT Podiatry (podiatry.com) is a podiatrist-owned-and-run company that proudly serves as the largest provider of online CME to the podiatry profession. One of the key lectures in their online CME collection is highlighted below.


Advances in Wound Care and Off Loading

CPME 0.5 Credit



Christopher Bromley, DPM
Chairman, Foot and Ankle Surgery
Vassar Medical Center
Poughkeepsie, NY

PRESENT e-Learning System has designated an unrestricted educational grant from



to support this online education activity.

Christopher Bromley, DPM discusses risk factors for wound healing in the diabetic population. Dr Bromley outlines his recommendations for successful wound healing and the best methods for off-loading. He supports his discussion with case studies.

View this lecture for CME Credit today at <https://podiatry.com/lecture/87>