



New Approaches to Evaluating Patients with DFUs

Technological advances have improved diagnostic capabilities.

BY ADAM LANDSMAN, DPM, PHD AND REBECCA STACHEL

Treatment of foot ulcers in patients with diabetes has changed considerably over the last 30 years. The emphasis on treatment with advanced biologics stems from the realization that chronic wounds frequently require an external stimulus to launch the cascade of events that leads to healing. As our understanding of wound healing has improved, the role of growth factors and tissue components such as collagen has expanded as well. Similarly, we know that biofilms, peripheral neuropathy, mechanical pressure, wound depth, pH, bacterial contamination, exudate, and circulation also may affect the chances of our patients to achieve wound closure.

The complexity of the issues influencing wound healing has led to new diagnostic tools that may help us to close wounds, or at the very least, help us to understand what factor or factors may be contributing to the chronic nature of a wound. Historically, radiographs and MRI have been helpful in diagnosing the presence of infection, and may also help to understand the underlying mechanical forces when conditions such as Charcot neuroarthropathy, pes planus and pes cavus foot types exist.

Circulation is also crucial to wound healing. The “toe and flow” model¹ is common among wound care physicians and points to the need for collaborative efforts between foot and vascular specialists. In its

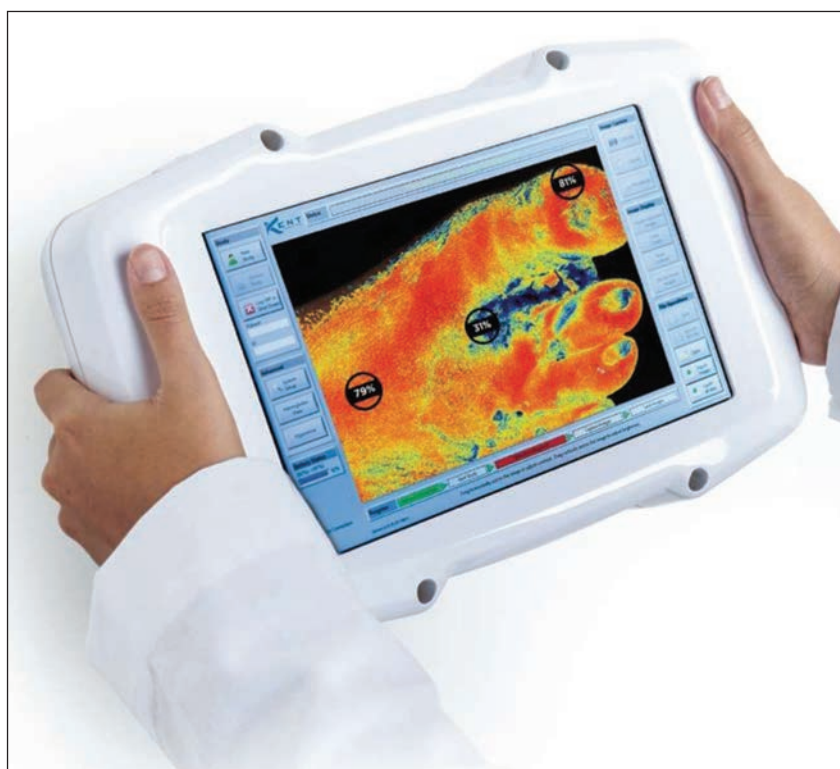


Figure 1: The SnapShotNIR (Kent Imaging, Calgary, AB, Canada) is a compact, handheld device that can capture a perfusion image of the foot in less than 9 seconds. It stores both the perfusion image and a standard color image, and has software available to make wound dimension measurements as well.

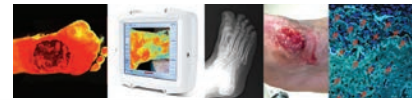most basic form, it is an over-simplification of the concept that wounds require blood to heal—either to use growth factors to facilitate communication for angiogenesis, mitogenesis, and chemotaxis—or to deliver oxygen to the wound bed. The reality of it is that blood flow to the wound, wound bed, and surrounding tissues is a crucial element in our under-

standing of how wounds form, and what it takes to heal them.

Matrix Metalloproteases (MMP)

The role of MMPs in wound healing is a double-edged sword. MMPs play a crucial role in wound healing, but also play a role in the prevention of wound healing. This dual

Continued on page 68



DFUs (from page 67)

role is based solely on the amount of MMP found in the bed of a wound. At lower levels, MMPs stimulate angiogenesis, but at higher levels, the enzymatic action serves to digest the tissues of the wound bed, resulting in damage. MMPs are also strongly associated with inflammation of the wound bed and adjacent tissues, and are frequently elevated in the presence of bacteria and biofilms. Detection of MMP levels is now possible with new technologies that are accessible in the clinical setting.

Under normal circumstances, MMPs are present only in minimal concentrations, but once a wound has formed, MMPs are rapidly expressed by numerous cell types including fibroblasts, keratinocytes, endothelial cells, and various inflammatory cells. Various growth factors and cytokines associated with wound healing, such as vascular endothelial growth factor (VEGF), also serve to activate the MMPs. Once activated, they can cause enzymatic degradation within the wound, which is beneficial at low concentrations and in specific regions of keratinocyte migration but detrimental at higher levels.²

Once detected, the MMPs can be regulated using a variety of approaches including photodynamic therapy, specialized dressings containing polyacrylate that binds the MMPs, or one can use a collagen material to act as a sacrificial tissue to bind excess MMPs.

pH

One simple measurement that can be used to assess the condition of a wound is pH. Using a simple dipstick type of measurement, pH can be determined. An excellent review of the influence of pH on wound healing was written by Schneider, et al.³ Not surprisingly, pH has both a direct and indirect effect on a large variety of biochemical reactions.

Historically, it has always been thought that because normal skin flora is slightly acidic, a lower pH value was always desired to stimulate wound healing. However, more recent studies have shown that the

Continued on page 71

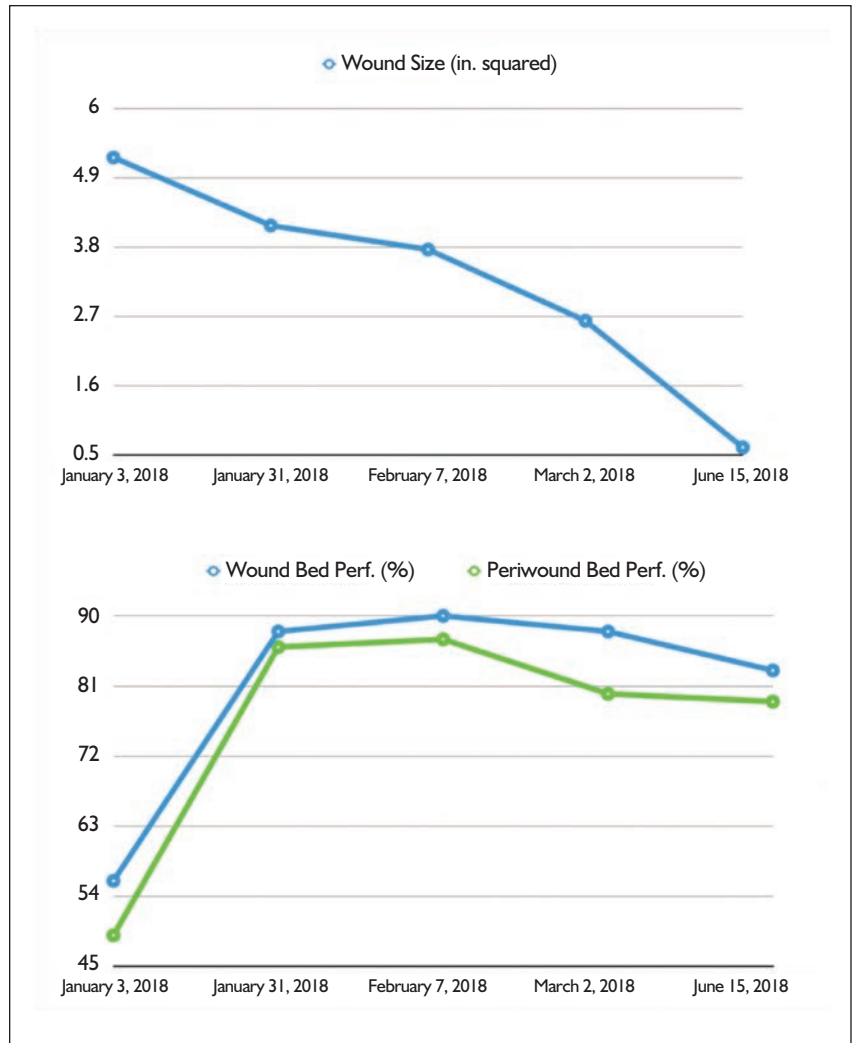
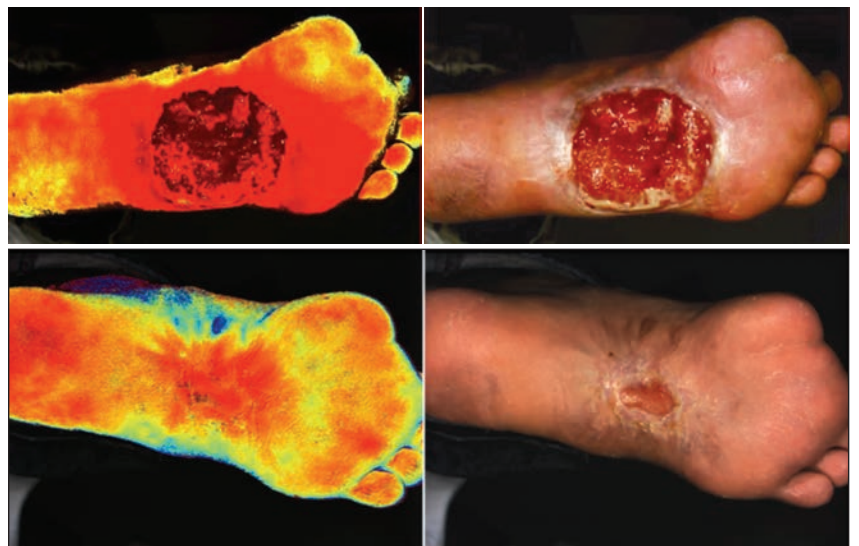
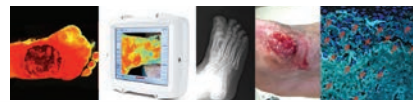

Figure 2: Using data collected from both the wound bed and the periwound areas, the level of oxygenated hemoglobin and tissue perfusion can be assessed. (a) In this case, a rapid decrease in wound size is directly correlated to an increase in wound and periwound tissue oxygenation. (b) NIRS image shows excellent perfusion of the wound bed, and periwound areas. Subsequent images show the resultant progression of healing.





DFUs (from page 68)

take rate for skin grafts actually improves in a more alkaline environment. In chronic wounds, there is an imbalance between growth and destruction of tissues, favoring destruction as long as the wound remains in the inflammatory phase.

By monitoring the pH within a wound, one can reach a consensus for the phase of healing that the wound is in. For example, acidosis tends to favor healing, while an increase in pH has been linked to decreased fibroblast migration and DNA synthesis. Low pH is also thought to increase the amount of available oxygen for cells involved in wound healing, i.e., the Bohr effect). Conversely, chronic wounds are normally alkaline in nature. This has been observed with venous leg ulcers and decubitus ulcers, in particular.

Although pH seems to drive a series of events in stimulation of wound healing, there does not appear to be a consensus on how to control or regulate it. Occlusive dressings have been shown to elevate the acidity of the wound bed and inhibit the growth of bacteria while promoting fibroblast growth. Thus, measurement of pH may be particularly useful when trying to assess the progression of healing (or lack thereof).

Temperature

Daily skin temperature monitored has been suggested as a method for predicting when a patient with diabetes is at increased risk for ulceration. Current mechanisms for measurement utilize optical instruments, or in some cases, temperature sensing mats, designed to passively measure temperatures every morning when a person with diabetes stands on one. The predictive value of temperature measurements is still in its infancy. Although there does not appear to be a strong correlation between absolute temperature measurements and the risk of ulcer formation, a significant difference in temperature between right and left feet shows some promise as a diagnostic tool.^{4,5}

Thermograms

Thermograms are maps of the temperature of the foot, as it changes

from location to location. Areas of increased heat may be detected when subtle changes in the autonomic nervous system develop. This has been correlated with the onset of other types of neuropathy as well, and may be a general reflection of the state of diabetic peripheral neuropathy. Historically, there has always been a strong correlation between neuropathy and the development of diabetic foot ulcers. It

late the ratio of oxygenated to deoxygenated hemoglobin. The advantages to this system are a high degree of accuracy, rapid data collection over large areas of skin, and no need for dye injections. These devices are relatively low in cost and will greatly enhance the clinician's ability to assess and treat diabetic foot ulcers, or any wounds where ischemia may be an issue.

Thermograms are maps of the temperature of the foot, as it changes from location to location.

is important to keep in mind that thermograms are demonstrating changes in temperature, and do not necessarily correlate in any way with elevated mechanical pressures.

Vascular Perfusion

Many will argue that there is more to wound healing than simply restoring blood flow, but nearly everyone will agree that there is no chance of healing if blood flow to the wound is absent. Another consideration is whether reduced blood flow to a particular area predisposes a diabetic patient to subsequently developing an ulcer. Blood flow to the feet and toes can be monitored using various modalities. In the absence of palpable pulses, Doppler devices can be used to locate and evaluate major arteries as well as the digital ones. Light-based techniques such as pulse oximetry can be used to measure levels of oxygenation, and are frequently used by anesthesiologists as part of their surgical monitoring protocol. Laser Doppler can also be used to evaluate small areas of skin, while fluorescein dye injections can be used to gather much more detailed information across the entire surface of the foot.

Near Infrared Spectroscopy

Near infrared spectroscopy is the latest tool to become available for assessing skin oxygenation and perfusion. This system measures reflected light at specific wavelengths to calcu-

Ultimately, by diagnosing and treating poorly oxygenated tissues, the clinician is helping to achieve wound closure more quickly. For example, a patient with poor perfusion can be treated in a variety of ways, including oxygen by cannula or by hyperbaric therapy, vasodilators, avoidance of cold, and reduction in skin tension at the site of surgery. Making these adjustments earlier in the treatment process may greatly reduce the time to healing, thereby saving future medical costs associated with a greater number of office visits, and avoidance of complications such as infection and amputation. It may also help in the selection of appropriate adjunctive biologic materials. By intervening earlier in the healing process, it is possible to save some tissues before they become permanently damaged by ischemia.

Near infrared spectroscopy is now readily available for clinical applications. This system offers superior penetration of tissues as compared to visible light-based systems. The device allows the clinician to map out the presence of oxygenated hemoglobin and wound bed perfusion, both within the wound bed, and in the adjacent tissues. In a recent study, the versatility of this system was demonstrated.⁶

A sample from the SnapshotNIR device (Kent Imaging, Calgary, AB, Canada) is shown (Figure 1). One can follow the progression of wound

Continued on page 72

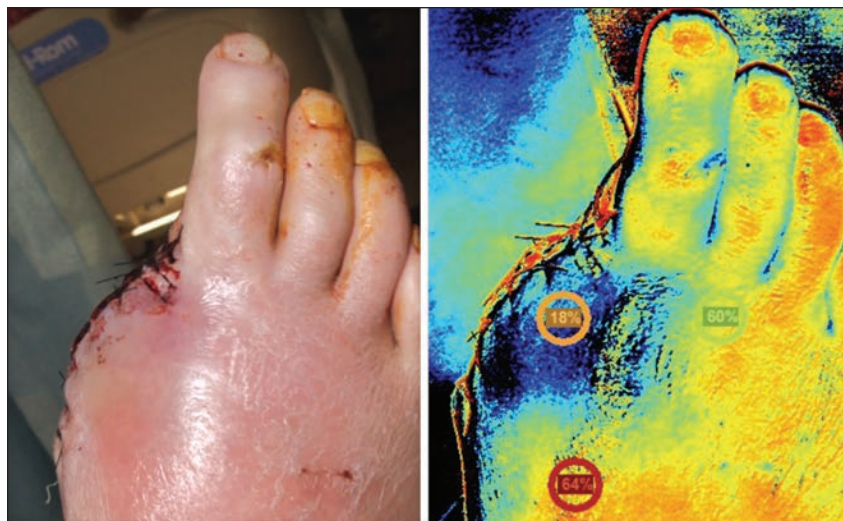
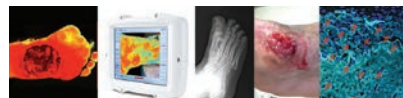
Figure 3: In this case, the clinical appearance of the foot was quite good following amputation of a gangrene toe. However, the NIRS image shows that the periwound tissue demonstrated only 18% oxygenated hemoglobin. Based on this poor level of tissue oxygenation, it was no surprise that this wound went on to dehisce one week later. It is significant that the NIRS image indicated that the tissues were at critical ischemic levels nearly a week before the wound went on to dehisce.

DFUs (from page 71)

healing using serial images. The graphs show the decrease in wound size as the percentage of oxygenation within the wound and in the peri-wound areas (Figure 2).

In other cases, the lack of perfusion is a strong indicator that a wound will be difficult, if not impossible to

the conditions that exist in the presence of the wound. New technologies allow clinicians to not only monitor what is going on within the wound, but also trigger responses to correct factors that may be preventing closure. The days where a clinician can simply look at a wound and make an educated guess about what is needed have begun to fade as these tools de-

Clinicians can be proactive in preventing wounds from developing, and can seek vascular intervention or oxygen therapy earlier in the treatment process.

heal. It has been previously shown that most wounds require greater than 40% oxygenated hemoglobin in order to achieve wound healing.

In cases where oxygenated hemoglobin levels drop below this threshold, wounds rarely progress to closure, and gangrene frequently may result. In some cases, this threshold may also have predictive value for determining levels of demarcation prior to amputation (Figure 3).

Conclusions

It is clear that the next horizon in the management of chronic wounds is to attain a better understanding of

velop and become readily available.

In our facility, we have already begun to monitor MMP levels. We have also begun to use the near infrared spectroscopy data in many ways that go beyond wound management. By developing a clear picture of tissue oxygenation and perfusion, it is now possible to predict which patients are at risk for future ulcers, in addition to looking at the real-time picture of vascular supply. There are tremendous financial benefits to having this type of information.

Clinicians can be proactive in preventing wounds from developing, and can seek vascular intervention

or oxygen therapy earlier in the treatment process. This should lead to faster wound closure, optimization of pH, and even reduction of dangerously elevated MMP levels. These types of diagnostic tests will ultimately lead to more efficient, cost-effective, and accurate assessments of chronic wounds, and what is needed to achieve closure. **PM**

References

- ¹ Rogers LC, Andros G, Caporusso J, Harkless LB, Mills JL Sr, Armstrong DG. Toe and flow: essential components and structure of the amputation prevention team. *J Am Podiatr Med Assoc.* 2010 Sep-Oct;100(5):342-8.
- ² Caley MP, Martins VL, O'Toole EA. Metalloproteinases and Wound Healing. *Adv Wound Care (New Rochelle).* 2015 Apr 1;4(4):225-234.
- ³ Schneider LA, Korber A, Grabbe S, Dissemond J. Influence of pH on wound-healing: a new perspective for wound-therapy? *Arch Dermatol Res.* 2007 Feb;298(9):413-20.
- ⁴ van Netten JJ, Prijs M, van Baal JG, Liu C, van der Heijden F, Bus SA. Diagnostic values for skin temperature assessment to detect diabetes-related foot complications. *Diabetes Technol Ther.* 2014 Nov;16(11):714-21.
- ⁵ Renero-C FJ. The thermoregulation of healthy individuals, overweight-obese, and diabetic from the plantar skin thermogram: a clue to predict the diabetic foot. *Diabet Foot Ankle.* 2017 Aug 16;8(1):1361298.
- ⁶ Landsman AS, Barnhart D, Sowa M. Near-Infrared Spectroscopy Imaging for Assessing Skin and Wound Oxygen Perfusion. *Clin Podiatr Med Surg.* 2018 Jul;35(3):343-355.



Dr. Landsman is Chief of the Division of Podiatric Surgery at Cambridge Health Alliance and Assistant Professor of Surgery at Harvard Medical School.



Rebecca Stachel is an Intern at Cambridge Health Alliance.