

## MIS Bunion Correction—Peacock Modified Reverdin-Isham-Bosch (PRIB)

By Don Peacock DPM, ABPS, Assistant Professor AAFAS

### Introduction

Distal first metatarsal osteotomies are widely accepted for treating HAV deformities.<sup>1</sup> These osteotomies lend themselves well to MIS techniques.<sup>2</sup> Drawbacks may arise due to shortening observed when performing through and through osteotomies by means of a burr.<sup>3</sup> The rationale behind modifying the Reverdin-Isham-Bosch is aimed at bringing about a MIS osteotomy which can directly address PASA and IM angle, and achieve plantar flexion and/or lengthening of the first ray when needed. I call this the PRIB procedure and is the acronym for Peacock, Reverdin, Isham, Bosch procedure.<sup>4,5</sup>

### Technique

A percutaneous punch incision is performed with a 64 blade and is made over the plantar medial border of the first ray where the metatarsal head fans out in the distal diaphyseal area. (Figure 1) The incision is continued down in a single cut until reaching the periosteum. From this position the 64 blade is used to underscore the capsule at the first metatarsal phalangeal joint employing a sweeping motion. Under fluoroscopy a 3.1 wedge burr is inserted and the medial prominence is resected from the first metatarsal head. (Figure 2) Pressure is applied to the

first metatarsal phalangeal joint area and the medial eminence is eliminated as bone paste. (Figure 3) (Figure 4)

The first step of the osteotomy involves a wedge osteotomy in the distal diaphyseal area of the first metatarsal leaving the lateral portion of the cortex intact. This is accomplished using a straight Isham burr. (Figure 5) The osteotomy is angled at a 35°-45 from dorsal distal to plantar proximal and is angled distally to help maintain length of the first metatarsal in patients with a relatively short 1st ray. (Figure 6) It can be made parallel to the 2nd metatarsal or proximal if desired. The final cut of the osteotomy involves completing the lateral cortex cut with a J stroke movement leaving a lateral plantar shelf. This maneuver will allow for further 1st ray lengthening and added stability for patients requiring plantar flexion of the 1st ray. (Figures 7,8,9)

The osteotomy is then shifted by inserting a Locke elevator through the incision site into the medullary canal of the 1st ray and using this as a fulcrum to transpose the osteotomy. (Figures 10,11) Prior to laterally shifting the osteotomy a percutaneous lateral release is done. (Figure 12) Thumb pressure can transpose the osteotomy in some patients. With the lengthening style cut the Locke elevator maneuver is easier. Note the plantar lateral shelf in Figure 11.

Subsequent to displacing the osteotomy fixation is accomplished via percutaneous K wire placement in a mod-

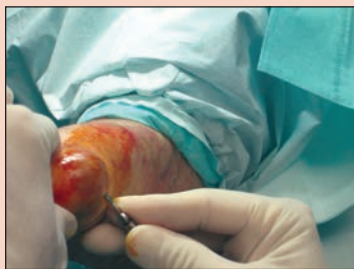

Figure 1

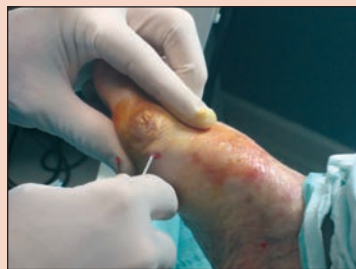

Figure 2

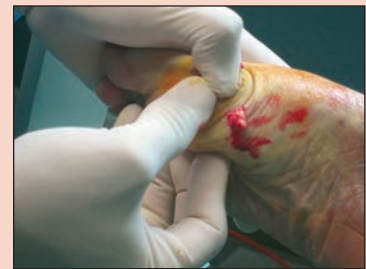

Figure 3

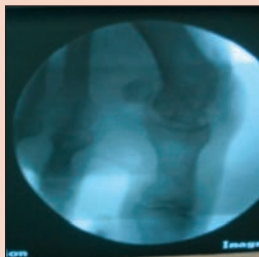


Figure 4

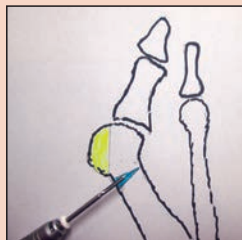


Figure 5




Figure 6

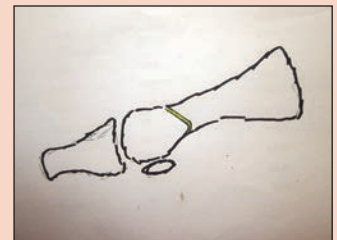


Figure 7

**MIS Bunion Correction** *(continued)*

ified Bosch version. (Figure 13) This fixation technique permits torquing to further close the PASA correction. Percutaneous fixation can also be performed proximal dorsal to plantar distal if desired. The osteotomy can be plantar-flexed by distracting the distal fragment and pressing the medullary portion of the fragment on to the plantar lateral shelf created by the osteotomy.

**Advantages of PRIB**

The advantage of this osteotomy is that it allows for correction of large intermetatarsal angles over 16 and can directly address PASA while limiting shortening realized with through and through osteotomies. Also, by creating the plantar lateral shelf, added stability is gained with patients demanding plantar-flexion of the first ray.

**Disadvantages of PRIB**

The most obvious disadvantage of this osteotomy is its more proximal placement than standard distal osteotomies, such as the Austin etc. This characteristic will result in a less stable osteotomy requiring fixation.

**Conclusion**

The PRIB technique borrows from already established osteotomies including the Reverdin-Isham and Bosch techniques. The procedure can be performed under local anesthetic in the office setting and the technique can be performed in 15 minutes. The PRIB is usually done in conjunction with an Akin osteotomy. Other than the

fluoroscopy no special equipment is needed and the cost of the K-wire is not prohibitive to office-based procedures. It's also a **Pretty, Reliable, Impeccable** and **Beneficial** way to correct HAV deformity. The preop and post op photos are Figures 14, 15, 16, and 17.

For more information on AAFAS visit [www.aafas.org](http://www.aafas.org) or [click here](#).

**References**

- <sup>1</sup> Austin DW, Leventen EO. A new osteotomy for hallux valgus: a horizontally V displacement osteotomy etc. *Clini Ortho* 1981;157:25-30
- <sup>2</sup> Schilero J: Minimal incision podiatric surgery. Principles and applications. *J Am podiatry Med Assoc* 75(11): 586-574, 1985
- <sup>3</sup> Zlotoff H: Shortening of the first metatarsal following osteotomy and its clinical significance. *J AM Podiatr Assoc* 67(6): 412-426, 1977
- <sup>4</sup> Isham S. The Reverdin-Isham procedure for HAV: *Clin Pod Med Surg* 1991;8: 81-94.
- <sup>5</sup> Bosch P, HAV correction method Bosch: 7-10 year follow up. *Foot Ankle Clin* 2000; 5:458-98.

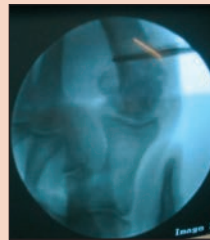


Figure 8

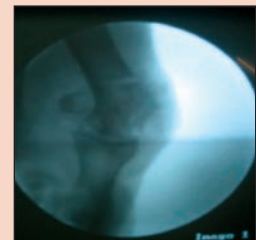


Figure 9

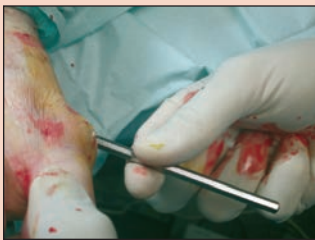

Figure 10

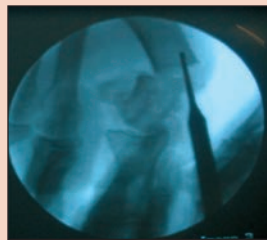


Figure 11

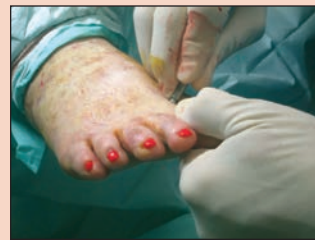

Figure 12

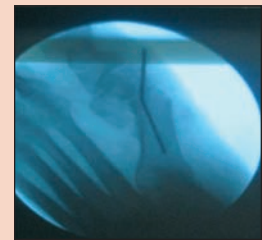


Figure 13

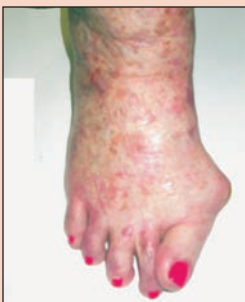

Figure 14

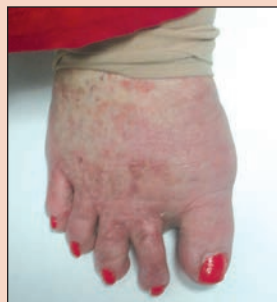

Figure 15

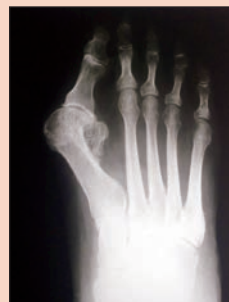

Figure 16

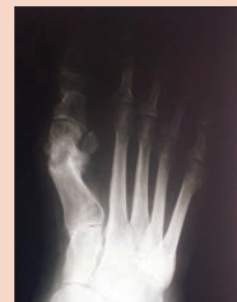

Figure 17